

# Extra-pulmonary NTM Infections

Jared J. Eddy, MD MPhil MSc

4/26/2024

*Assistant Professor of Medicine  
Division of Mycobacterial and Respiratory Infections  
National Jewish Health*

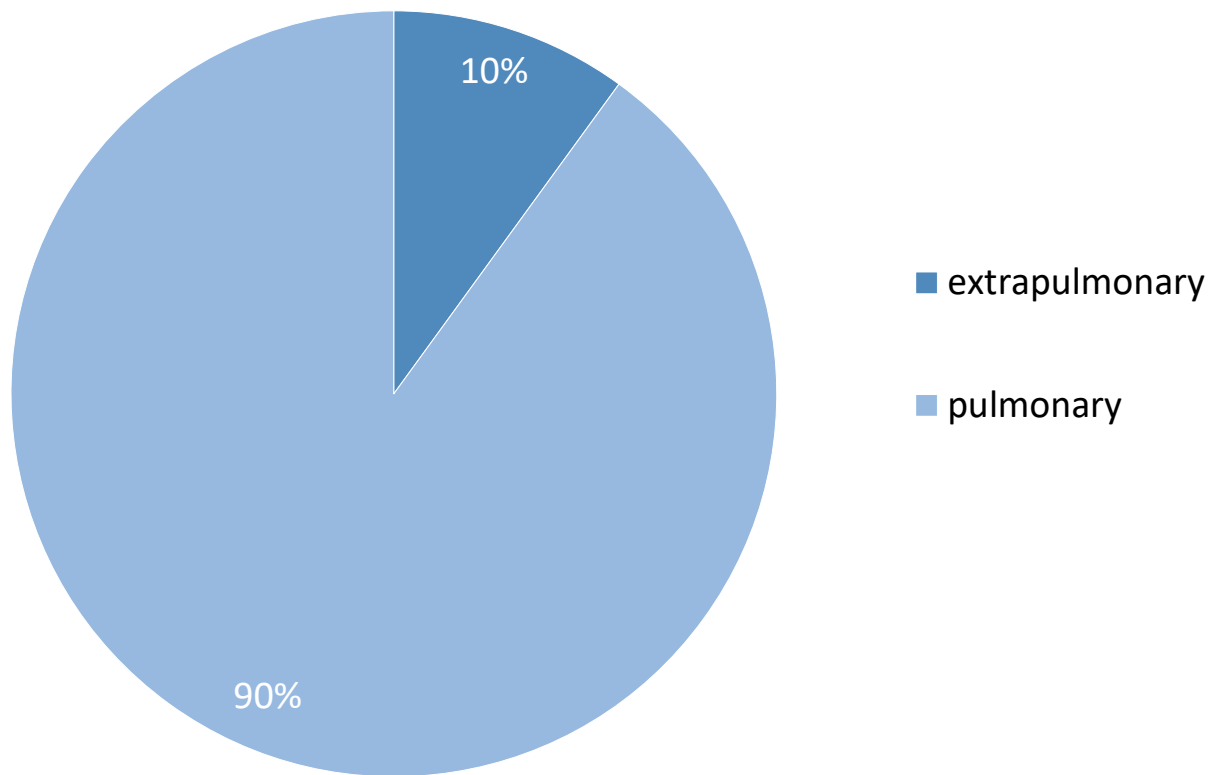
# Disclosure

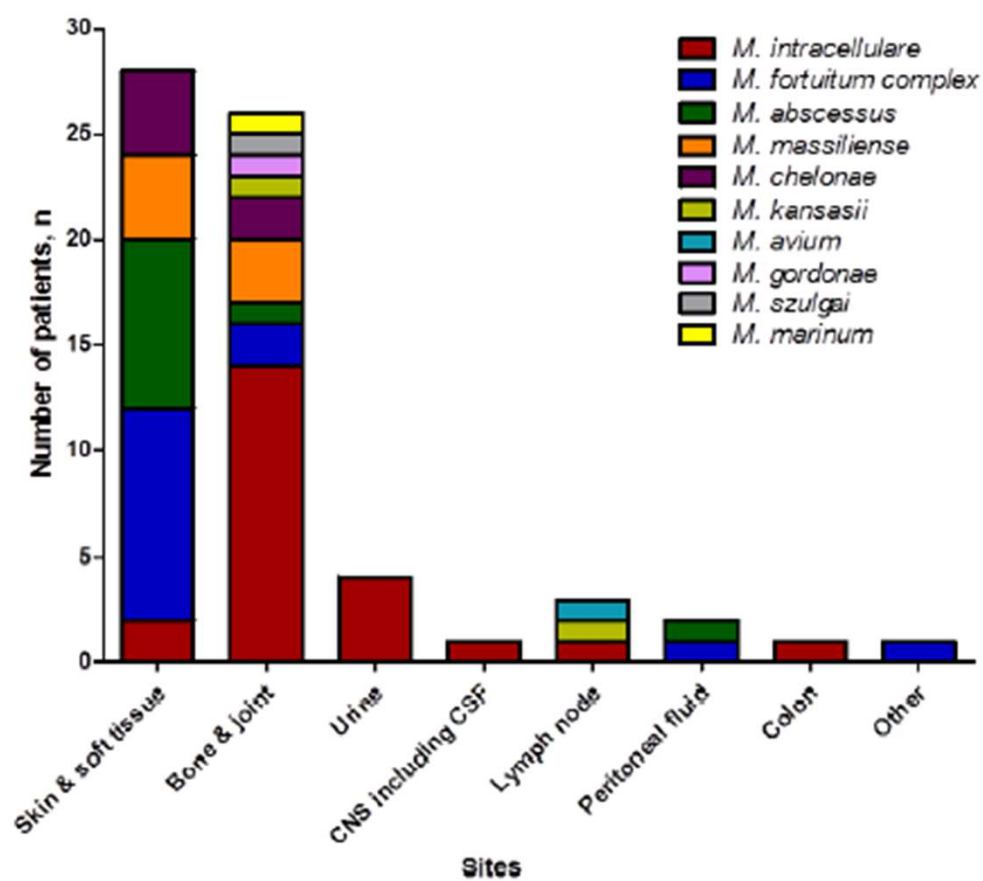
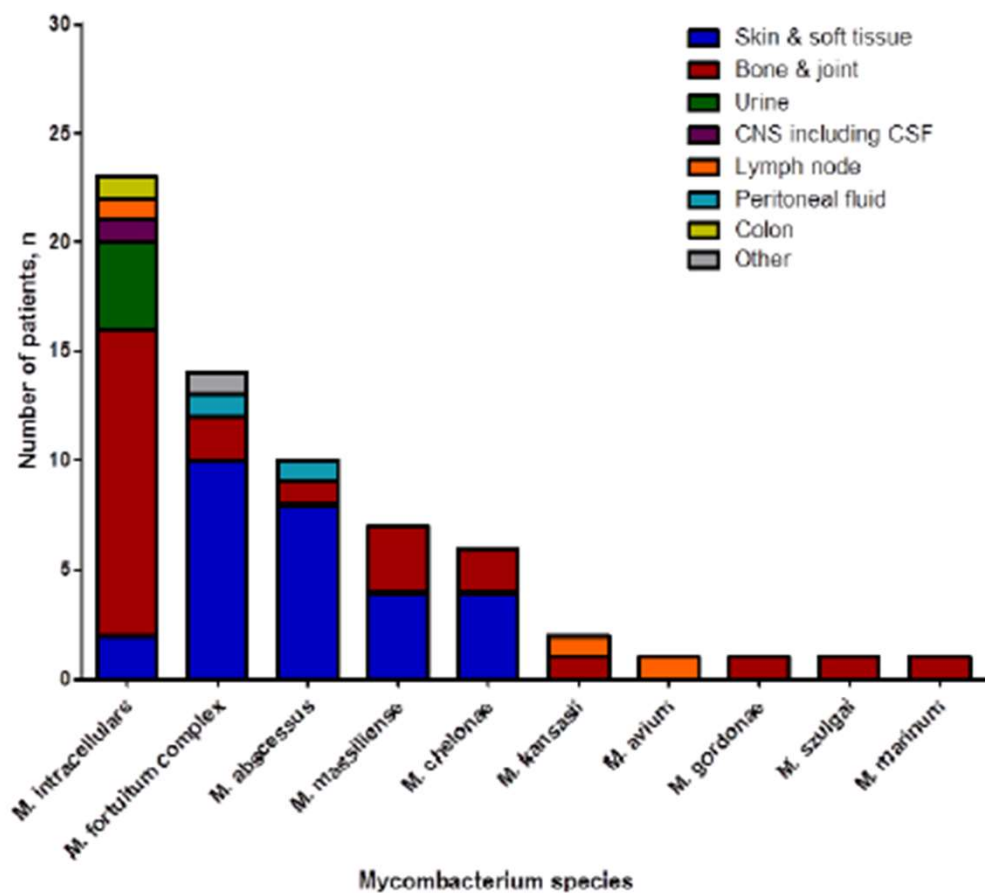
- Nothing to disclose

# Objectives

- Introduce the species commonly identified in extrapulmonary infections
- Illustrate several different clinical manifestations
- Review risk factors for extrapulmonary infection
- Discuss the medical and surgical approach in patients with extrapulmonary disease

# Clinical Manifestations of NTM





# Criteria for NTM disease

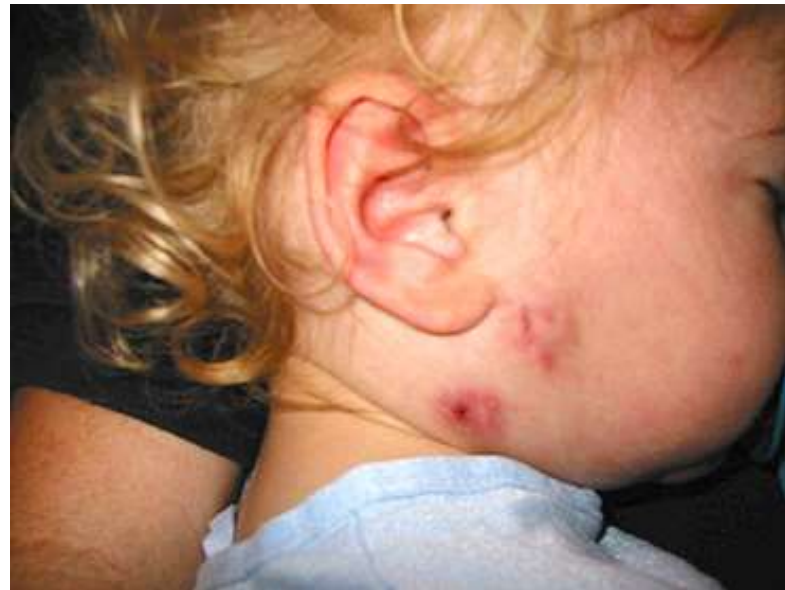- Extrapulmonary
  - Isolation of NTM from a sterile site
  - Concomitant signs of inflammation
- Preferable to send tissue biopsy or fluid aspirate
- Wound swab= low yield
- Send for acid fast smear and culture

# Lymphadenitis

<sup>1</sup>*Tuber Lung Dis* 1995;76:300–310

<sup>2</sup>*Pediatr Infect Dis J.* 2008;27(10):920

- Sub-acute/chronic unilateral cervical nontender lymphadenitis in children (< 5 years old)
- *M. avium* complex, *M. scrofulaceum*, *M. malmoense*, *M. haemophilum*
- ~300 cases/year in US
- Risk factors
  - Children
  - Immunocompromised
  - Protective effect of BCG vaccination?<sup>1</sup>
- Diagnosis: LN biopsy
- Treatment:
  - surgical excision (95% cure)
  - Observation<sup>2</sup>



# Buruli Ulcer

- Caused by *M. ulcerans* (neglected tropical disease)
- Exotoxin (mycolactone)
- Environments with stagnant water?
- Tx: rifampin + streptomycin → all oral regimen; wound management, surgery?

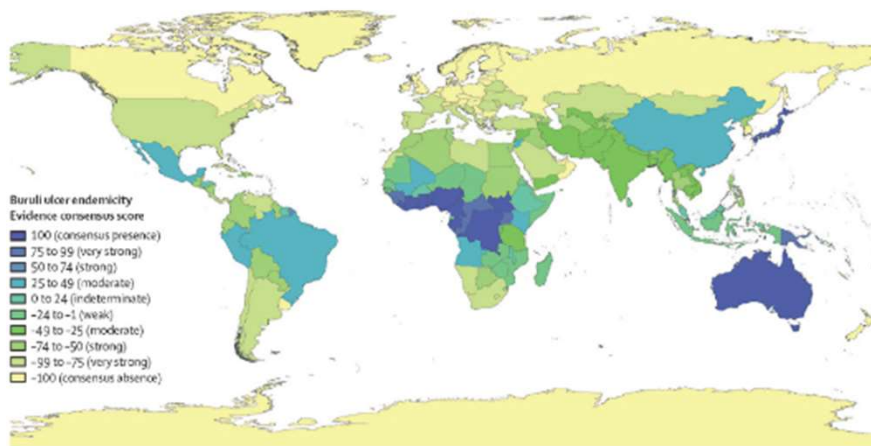
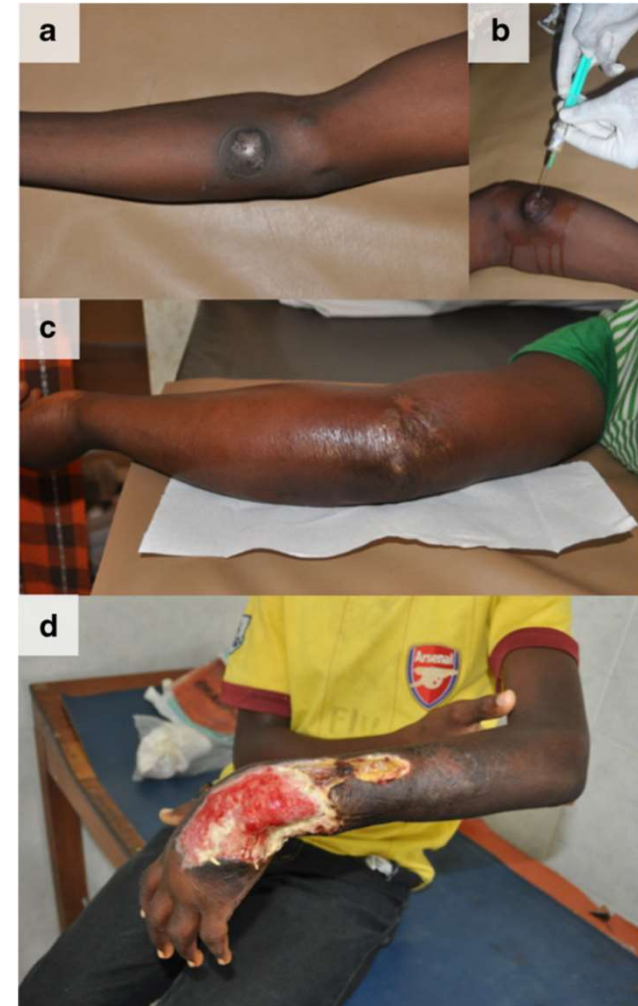

Figure 4 Evidence consensus for Buruli ulcer presence and absence worldwide

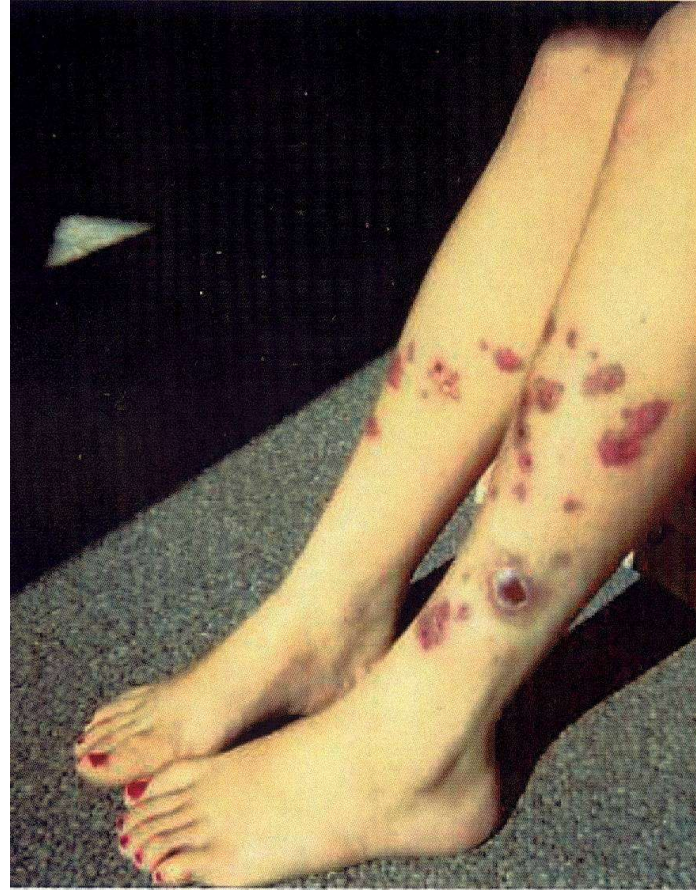

Curr Trop Med Rep  
2018;5(4):247-256

Lancet Glob Health  
2019;7(7):e912-e922

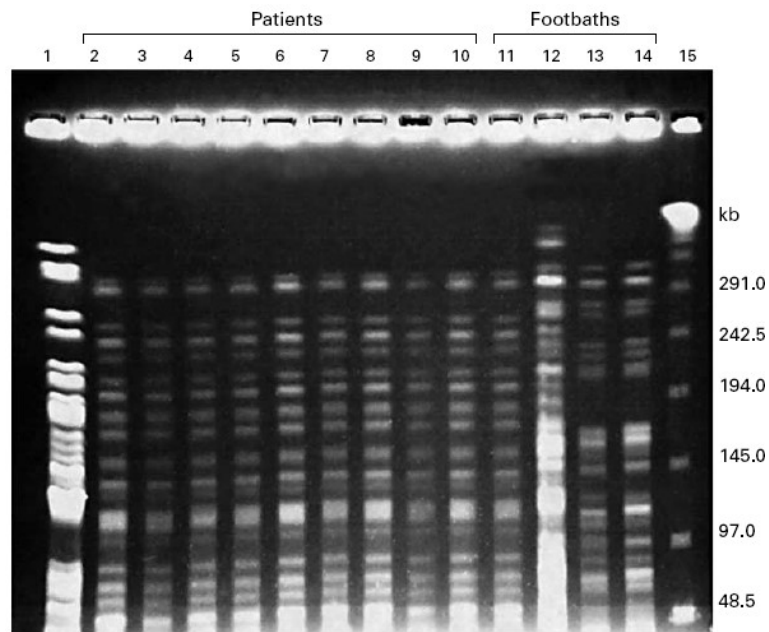


# Nail salon outbreaks



NEJM 2002;346:1366-71

# Nail salon outbreaks



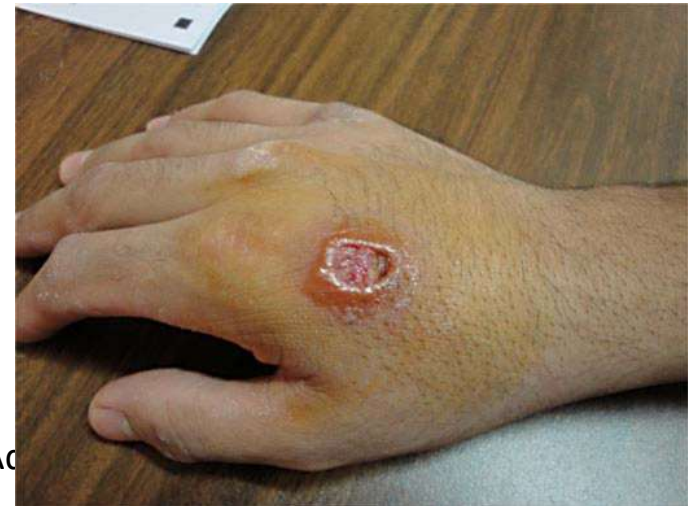Shaving the legs with a razor before pedicure was a risk factor for infection (70 percent of patients vs. 31 percent of controls)

## Nail Salon Outbreaks: *M. fortuitum*

- Surgical resection is NOT necessary
- Early antibiotics benefit patients with more than one furuncle
- Untreated skin infection may be self limited
- Mean duration 4 months
- Recommend: quinolone + tetracycline

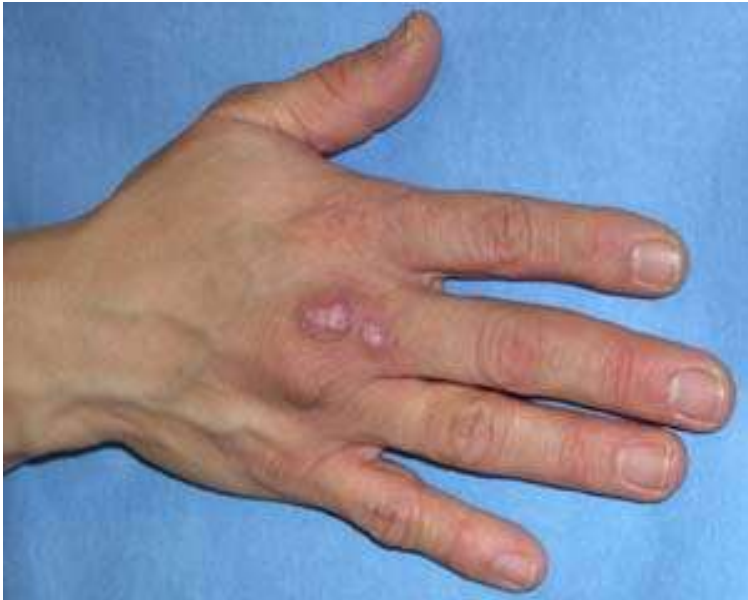# Fish Tank Granuloma: *M. marinum*

- Solid nodule, plaque or ulceration
- Culture: 33 degrees Celsius
- Risk factors:
  - Contact with aquatic environment (fresh or saltwater)
- Diagnosis: Biopsy with AFB smear and culture



Ac

# Fish Tank Granuloma: *M. marinum*



- Treatment: 3-4 months with two active agents
  - Clarithromycin/ azithromycin
  - Ethambutol
  - Rifampin
  - Trimethoprim-sulfamethoxazole
  - Doxycycline/minocycline
- Surgery:
  - tendonitis/arthritis
  - failure to respond to standard therapy
- Heat

# M. Marinum tenosynovitis



- Multiple surgeries
- Azithromycin, ethambutol, rifampin
- Clofazimine
- IV amikacin (limited by tinnitus)
- Drug levels (history of gastric bypass)

# Skin, Soft Tissue and Bone Infection

- Nodular skin lesions or ulceration
- Consequence of dissemination or direct inoculation
- Typical pathogens:
  - *Slow growing* (*M. ulcerans*, *M. marinum*, *M. haemophilum*, *M. avium* complex)
  - *Rapidly growing* (*M. abscessus*, *M. chelonae*, *M. fortuitum*)
  - Incidence: unknown
- Diagnosis: recommend surgical biopsy of the skin, soft tissue or bone for afb smear and culture
- ***Beware steroids for “immune condition” when in fact NTM is the cause***

# Skin, Soft Tissue and Bone Infection

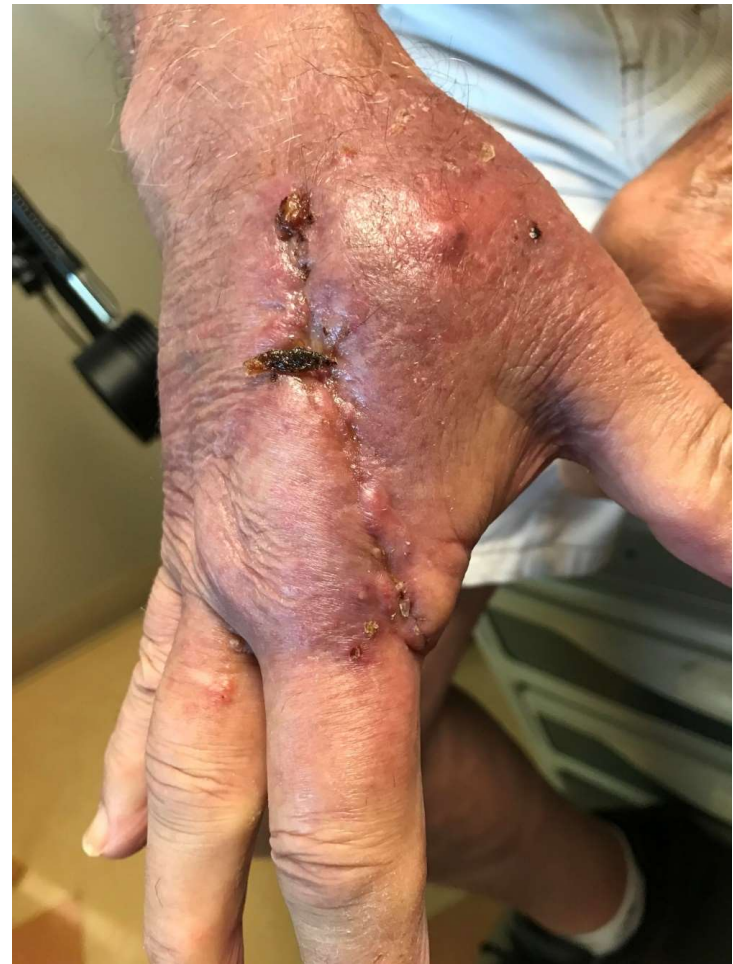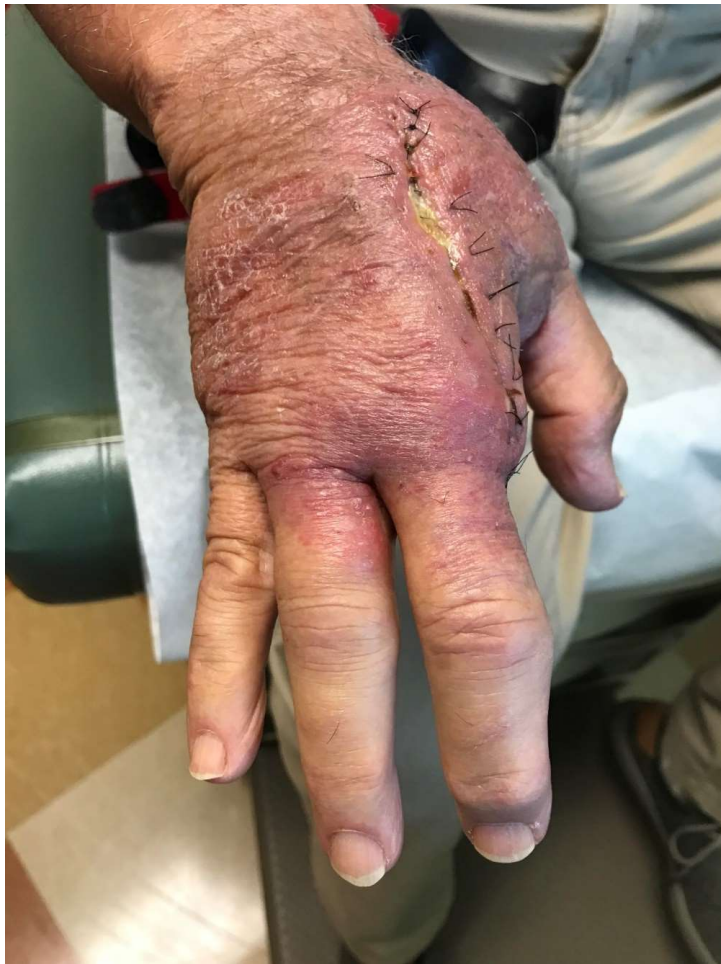- Treatment: 2-4 active drugs (or more)
  - Superficial
    - 4 months (or longer) for soft tissue infection
  - Deep
    - 3-6 months of IV therapy often required (with orals)
    - 6-12 months total duration (or longer) for cartilage/bone infection
- Treatment length is inversely proportional to the degree and effectiveness of debridement
- *Erm* gene functionality (inducible macrolide resistance?) for rapidly growing mycobacteria (RGM)
- Treat until no ***clinical or radiological (+/- microbiological)*** evidence of infection and often further therapy beyond this point for residual undetectable infection



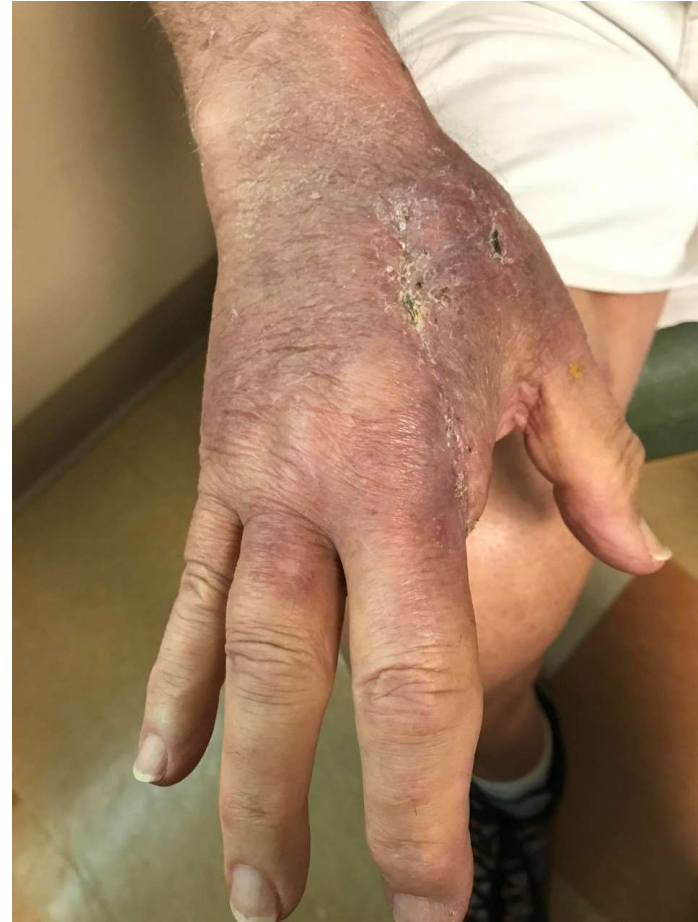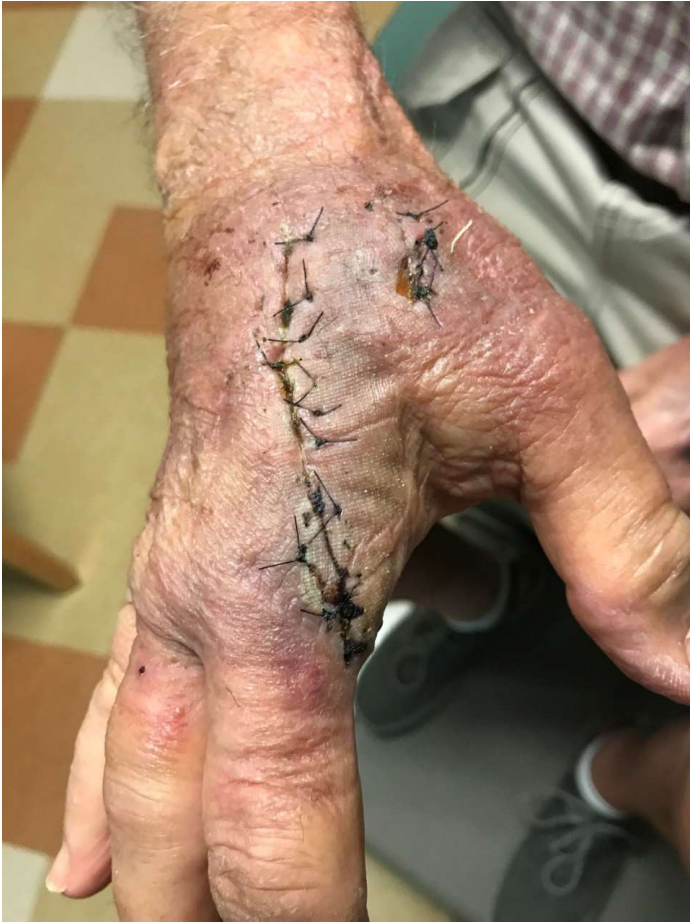# Surgical Considerations

- **Surgical debridement usually required**
  - especially organisms less sensitive to antibiotics (e.g., *M. abscessus*)
  - infections of closed space (tendon, joint)
  - removal of foreign material
- **Best chance of cure with first debridement, inadequate debridement prolongs antibiotic therapy**
- Obtain cultures with every surgical intervention
- Bring back to surgery for persistent/recurrent disease on imaging
  - Antibiotic holiday several weeks prior to repeat surgery
    - Help with toxicities (limited effect until proper debridement)
    - May help with further culture growth from new specimens

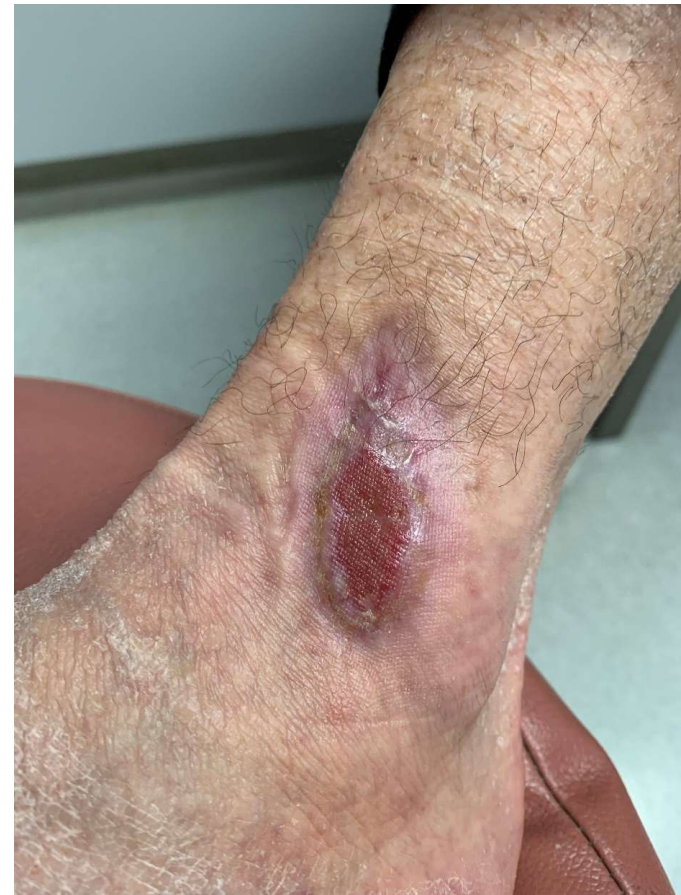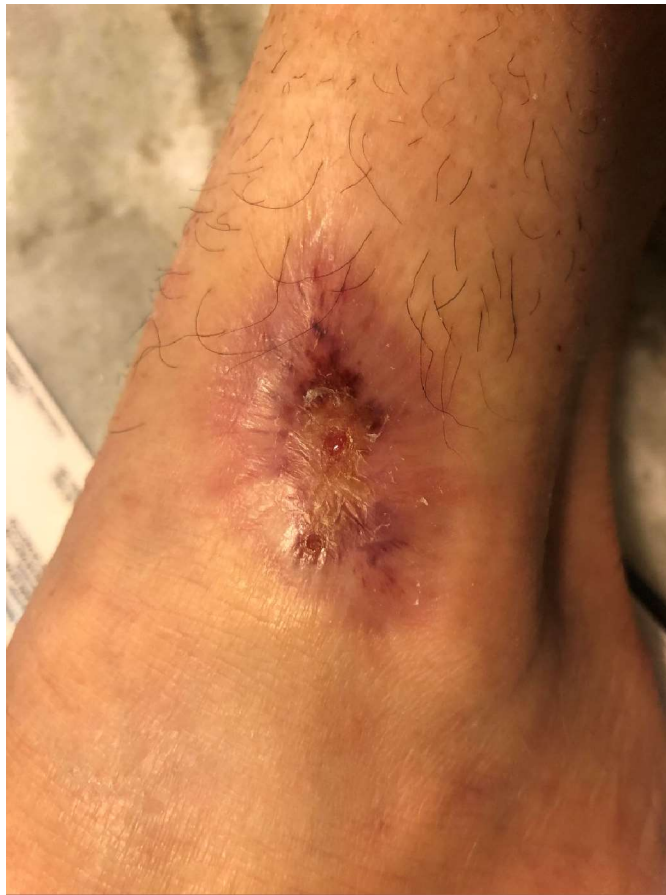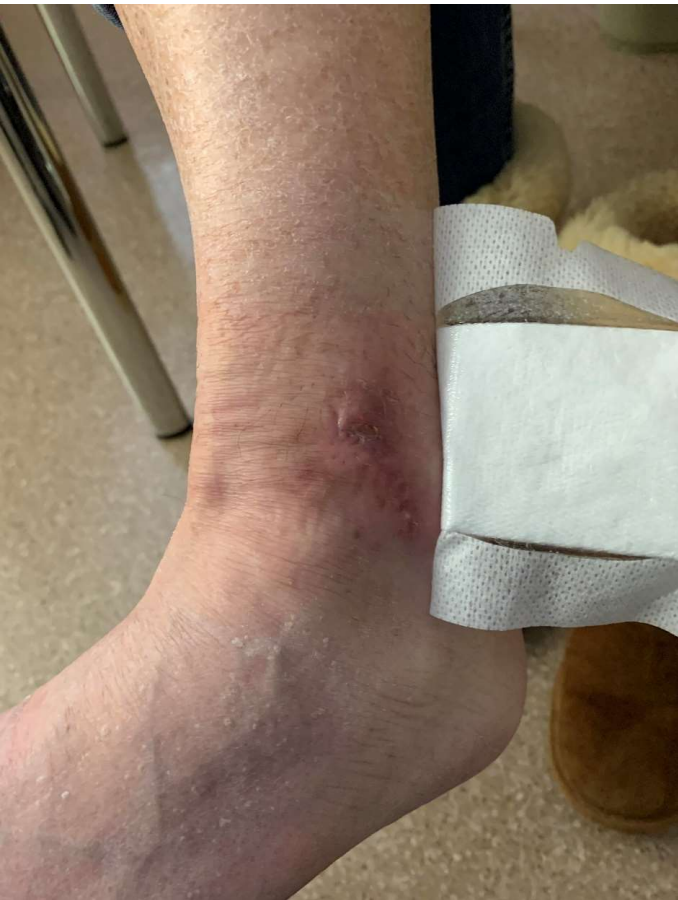# M. Abscessus subsp. abscessus hand infection



Autoimmune hemolytic anemia (prednisone), hearing loss  
Tx: IV imipenem + ceftazidime, clofazimine, omadacycline



M. Abscessus subsp. abscessus ankle infection  
amik/imi/clofaz/linez → imi/ceftaz/clofaz/linez/omada



# Skin and soft tissue infection (RGM)

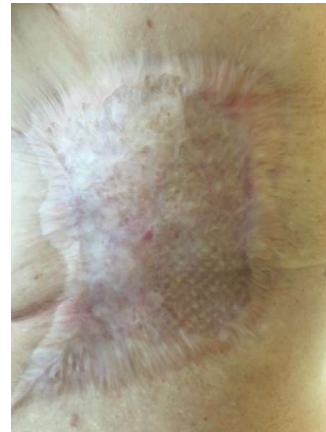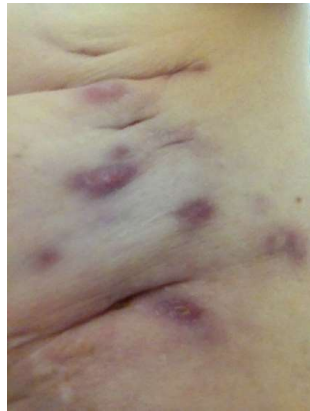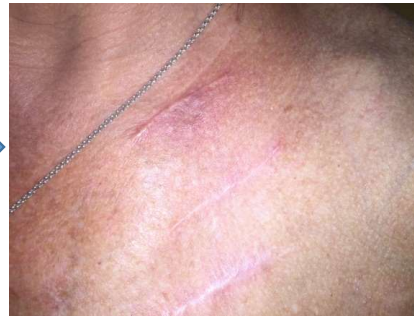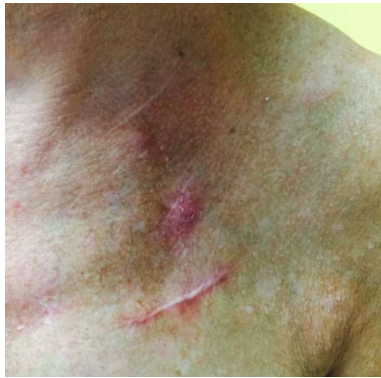Age/s ex	Comorbidity	Location	Cause	Organism	Surgery	Antibiotics (weeks)	Outcome (months p Rx)
71 M	DM, CKD	Left palm	trauma	<i>M. fortuitum</i>	I/D	AMK,CLR,CIP (4) CLR,CIP (20)	Cure (4)
68 F	Vasculitis	RLE	Public bath	<i>M. fortuitum</i> , <i>ulcerans</i> and <i>marinum</i>	None	AMK,CFX,RIF,CLR(3) CLR/MOX (13)	Cure (2)
72 M	COPD*	R shoulder	Post-op 4wks, public bath?	<i>M. fortuitum</i>	I/D	AMK,CFX,CLR (4) DOX,MOX (24)	Cure (3)
71 F	None*	R shoulder	Post-op 6 wks, public bath?	<i>M. fortuitum</i>	I/D	AMK,CFX,CLR (4) CLR,MOX (20)	Cure (4)
78 F	DM,CKD, AI	Left foot	Public bath	<i>M. chelonae</i>	Amputa- tion	AMK,CFX,CLR (2) RFT,CLR (6) CLR (3)	Death

\* Hardware in place for rotator cuff repair

AMK, amikacin; CFX, cefoxitin; CLR, clarithromycin; CIP, ciprofloxacin;  
MOX, moxifloxacin;RFT,rifabutin; DOX, doxycycline

Infect Chemother 2013;45(1):85-93.

# *M. abscessus* Post Fat transfer



## Abscesses due to *Mycobacterium abscessus* Linked to Injection of Unapproved Alternative Medication

Karin Galil,\* Lisa A. Miller,† Mitchell A. Yakrus,\*  
Richard J. Wallace Jr.,‡ David G. Mosley,§ Bob England,§  
Gwen Huitt,¶ Michael M. McNeil,\* and Bradley A. Perkins\*

\*Centers for Disease Control and Prevention, Atlanta, Georgia, USA;  
†Colorado Department of Public Health and Environment, Denver, Colorado,  
USA; ‡University of Texas Health Center, Tyler, Texas, USA; §Arizona  
Department of Health Services, Phoenix, Arizona, USA; and ¶National  
Jewish Medical and Research Center, Denver, Colorado, USA

An unlicensed injectable medicine sold as adrenal cortex extract (ACE\*) and distributed in the alternative medicine community led to the largest outbreak of *Mycobacterium abscessus* infections reported in the United States. Records from the implicated distributor from January 1, 1995, to August 18, 1996, were used to identify



Search

# EMERGING INFECTIOUS DISEASES®

ISSN: 1080-6059

Volume 22, Number 8—August 2016

### Synopsis

## Multistate US Outbreak of Rapidly Growing Mycobacterial Infections Associated with Medical Tourism to the Dominican Republic, 2013–2014<sup>1</sup>

David Schnabel✉, Douglas H. Esposito, Joanna Gaines, Alison Ridpath, M. Anita Barry, Katherine A. Feldman, Jocelyn Mullins, Rachel Burns, Nina Ahmad, Edith N. Nyangoma, Duc T. Nguyen, Joseph F. Perz, Heather Moulton-Meissner, Bette J. Jensen, Ying Lin, Leah Posivak-Khouly, Nisha Jani, Oliver Morgan, Gary W. Brunette, P. Scott Pritchard, Adena H. Greenbaum, Susan M. Rhee, David Blythe, Mark Sotir, and the RGM Outbreak Investigation Team

#### On This Page

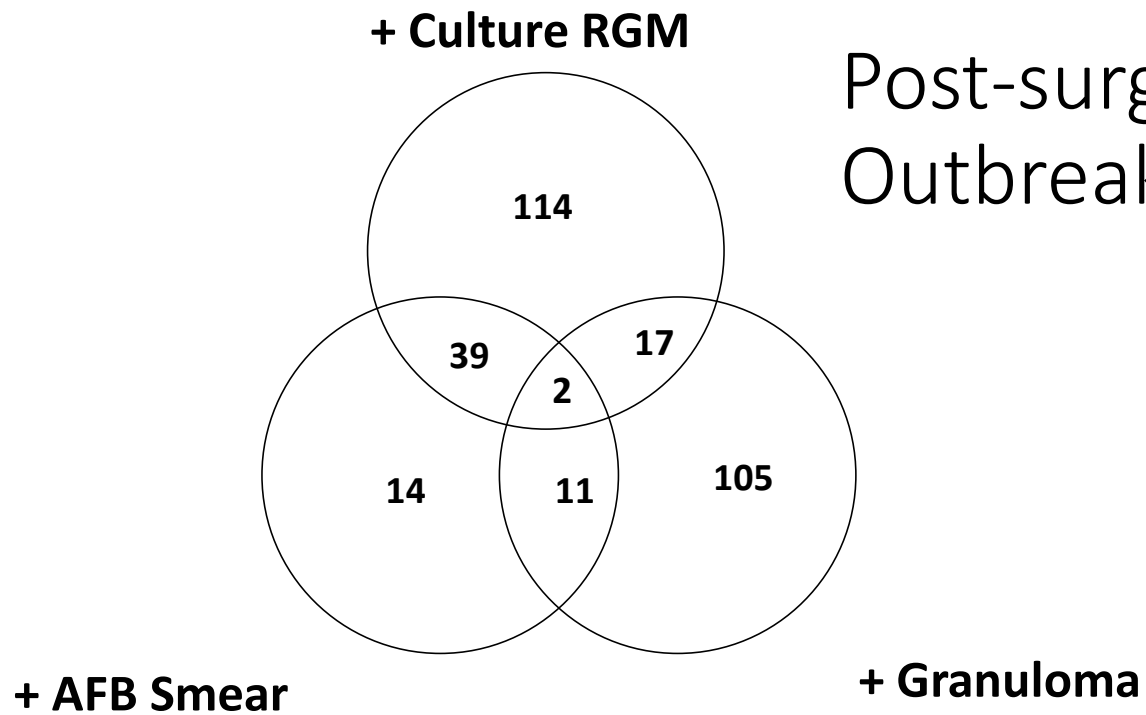
[Methods](#)

[Results](#)

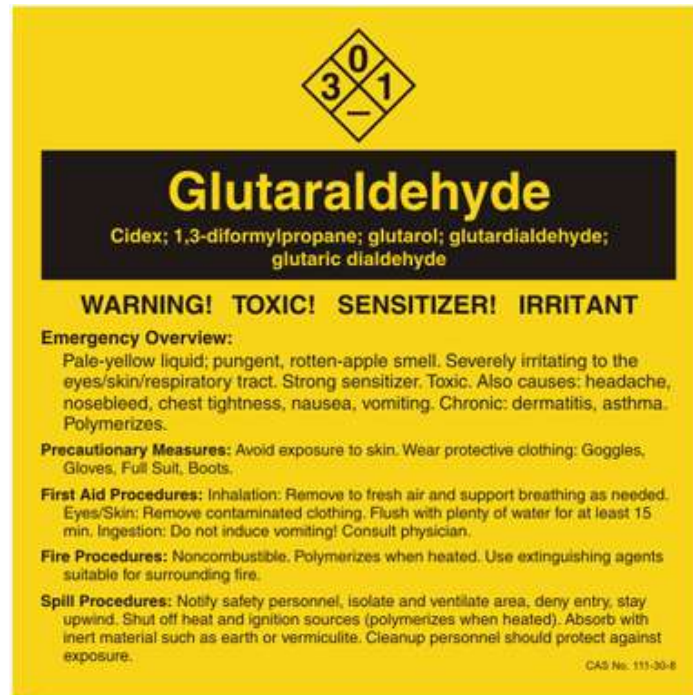[Clinical Courses and Treatment](#)

[Discussion](#)

# Post-surgical Outbreaks







- *M. massiliense* BRA100 strain
  - resistant to high gluteraldehyde concentrations (up to 7%)
  - substituted with orthophthaldehyde (OPA) and peracetic acid (PA)-based solutions for high level disinfection



## *Notes from the Field:* Nontuberculous Mycobacteria Infections After Cosmetic Surgery Procedures in Florida — Nine States, 2022–2023

Weekly / January 25, 2024 / 73(3);66–67

[Print](#)

Katharine E. Saunders, DNP<sup>1,2</sup>; Juliana M. Reyes, MS<sup>2</sup>; Lorrie Cyril, MPH<sup>2</sup>; Molly Mitchell, PhD<sup>3</sup>; Stephanie Colter, DrPH<sup>2</sup>; Jalysa Erskine, MPH<sup>2</sup>; Kiara X. McNamara, DNP<sup>4</sup>; Jennifer C. Hunter, DrPH<sup>4</sup>; Kiran M. Perkins, MD<sup>4</sup>; Argentina Charles, MPH<sup>2</sup> ([VIEW AUTHOR AFFILIATIONS](#))

### Summary

#### What is already known about this topic?

Nontuberculous mycobacteria (NTM) have been reported as a cause of health care–associated infections.

#### What is added by this report?

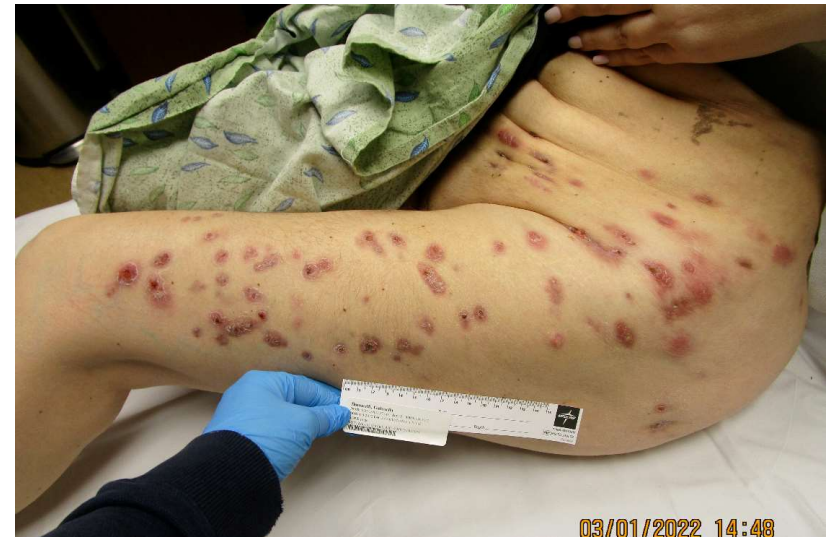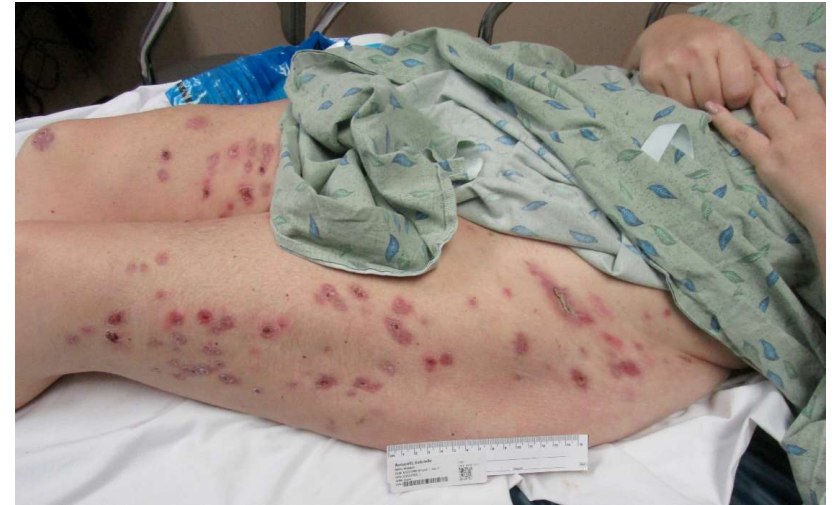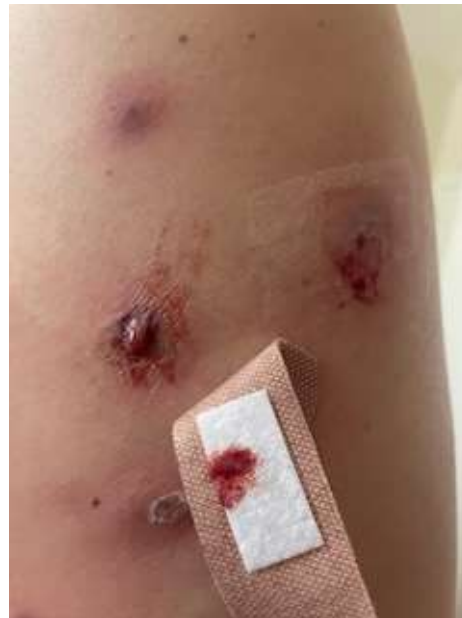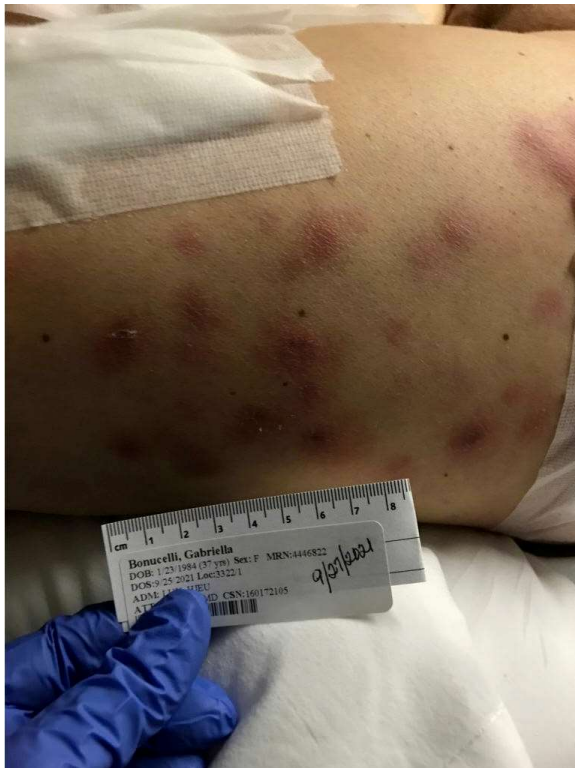Investigation of a case of NTM infection in a patient who received a cosmetic surgical procedure in Florida identified a total of 15 cases in nine states in patients who received cosmetic surgical procedures at the same facility in Florida. Multiple lapses in infection control and prevention were found at an outpatient cosmetic surgery clinic operating with the same staff members.

#### What are the implications for public health practice?

Health care providers should have a high index of suspicion for extrapulmonary NTM when evaluating patients for postsurgical infection after cosmetic procedures and should be aware of the threshold for notifying public health officials of these cases.

# Liposuction (8/2021)

9/27/'21 (left, center), before antibiotics  
12/15/'21 (top right), 6 weeks on antibiotics  
1/3/2'22 (bottom right), 8 weeks on antibiotics



## Audience Question:

	<i>M. abscessus group</i>	
ANTIBIOTICS	MIC mcg/mL	INTRP
Amikacin (IV)	32	I
Augmentin	>32/16	NI
Azithromycin	<=16	NI D1
Azithromycin (14 Day)	<=16	NI D2
Cefepime	>32	NI
Cefotaxime	>64	NI
Cefoxitin	32	I
Ceftriaxone	>64	NI
Ciprofloxacin	>8	R D3
Clarithromycin	<=0.25	S D4
Clarithromycin (14 Day)	0.5	S D2
Clofazimine	<=0.5	NI
Clofazimine/Amikacin	<=0.5/2	NI D5
Doxycycline	>16	R
Gentamicin	4	NI
Imipenem	8	I D6
Kanamycin	<=8	NI
Linezolid	>16	R
Minocycline	>8	NI
Moxifloxacin	>4	R
Tigecycline	1	NI
Tobramycin	>16	R D7
Trimethoprim/Sulfamethoxazole	>4/76	R
x Compliance Statement		* D8

### *Mycobacterium abscessus group*

#### Drug Resistance Markers of Various NTM

FINAL

11/17/21

A cytosine has been detected at position 28 (T28C) of the erm(41) gene.  
THIS SUGGESTS SUSCEPTIBILITY TO MACROLIDES.

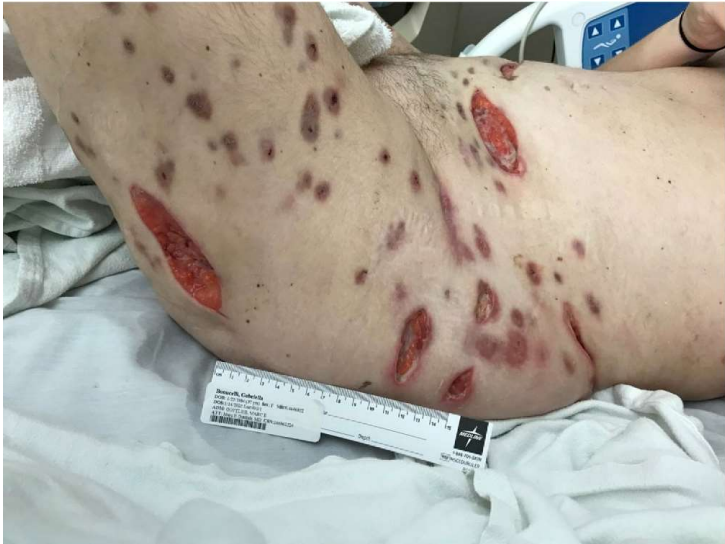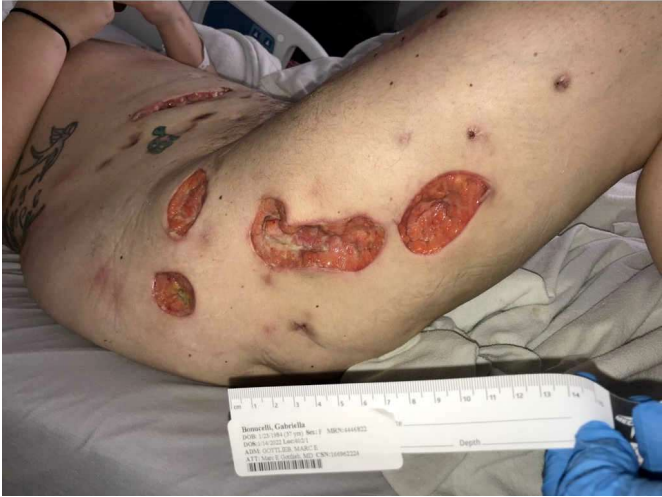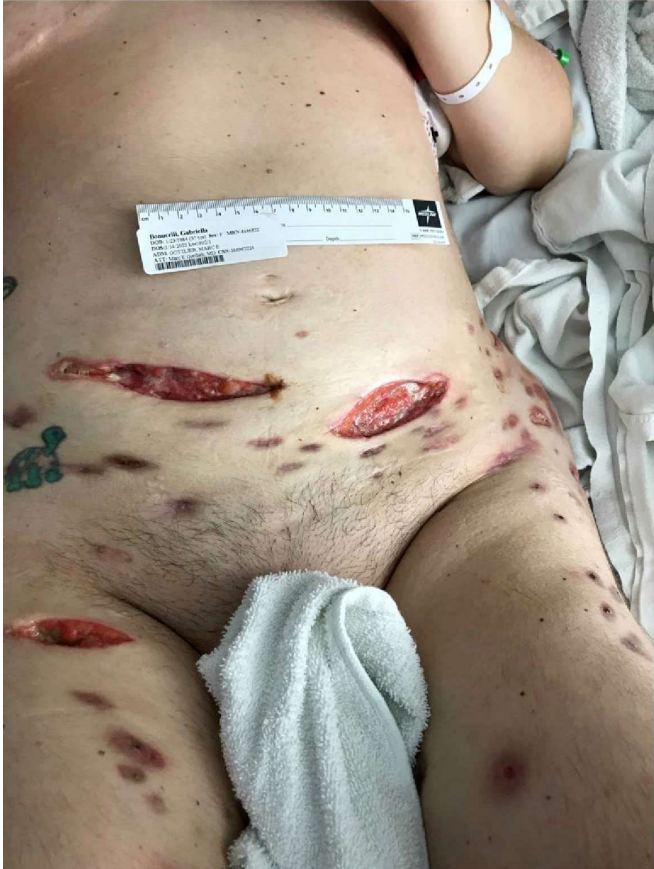No mutations are present at rrl.  
ACQUIRED (HIGH LEVEL) MACROLIDE RESISTANCE IS NOT PREDICTED.

No mutations are present at rrs.  
THIS SUGGESTS SUSCEPTIBILITY TO AMINOGLYCOSIDES.

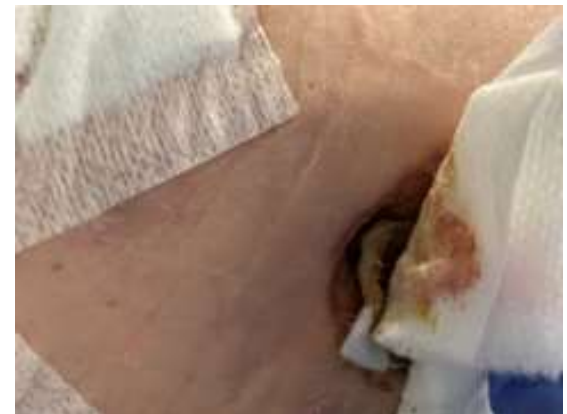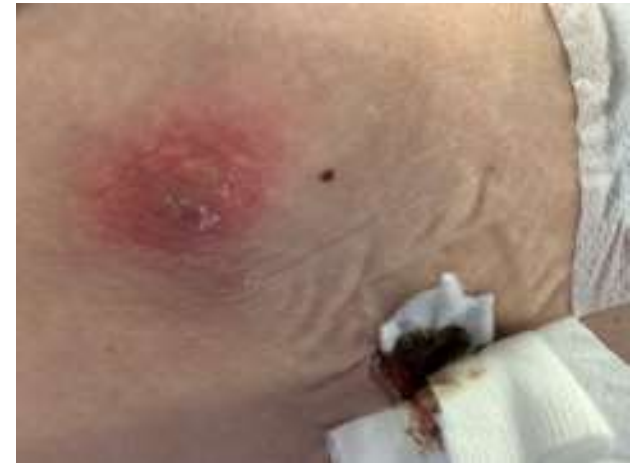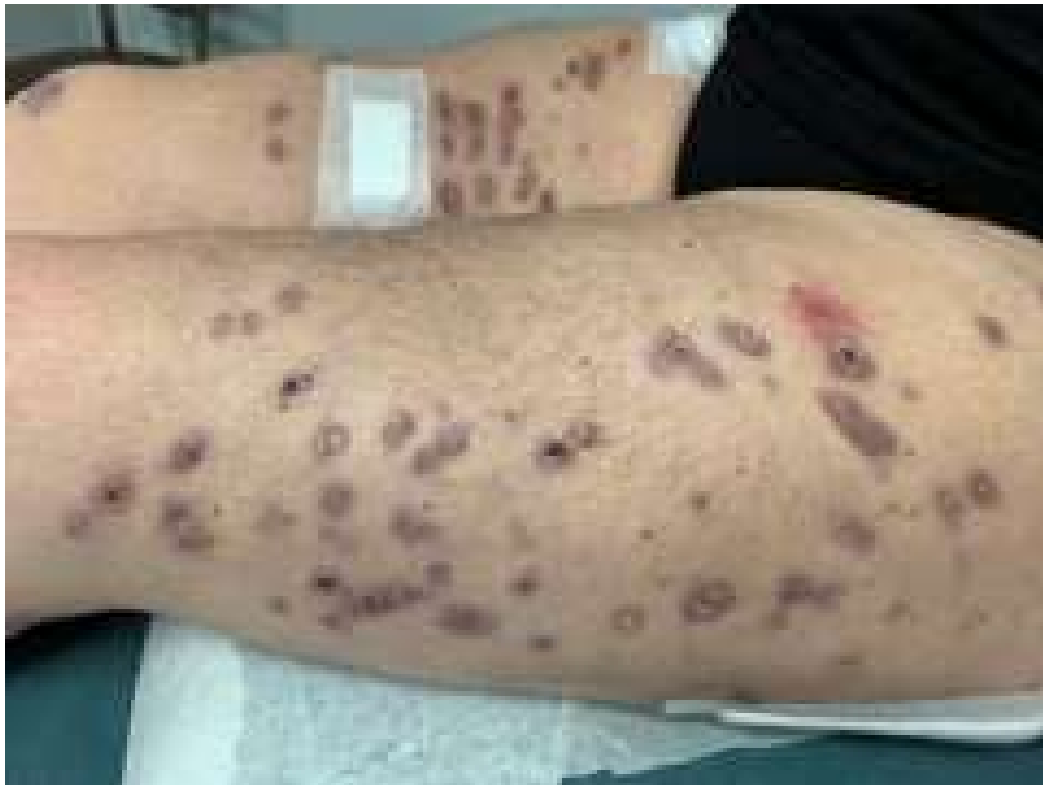## What Antibiotic Therapy do you choose?

- 1) Amikacin IV, Clarithromycin, Cefoxitin IV
- 2) Clarithromycin, Tigecycline IV, Linezolid
- 3) Azithromycin, Eravacycline IV...Clofazimine
- 4) Amikacin IV , Azithromycin, Imipenem IV,  
Omadacycline PO/IV
- 5) Amikacin IV, Azithromycin, Eravacycline  
IV... Clofazimine

# Following 1/11/2022 Surgery



# National Jewish Visit 2/2022, new lesions on therapy



# Rapidly-growing NTM: new lesions on therapy

Annals of Internal Medicine®

Search Jour

LATEST ISSUES IN THE CLINIC JOURNAL CLUB MULTIMEDIA CME / MOC AUTHORS / SUBMIT

Articles | 15 September 1993

## Clinical Trial of Clarithromycin for Cutaneous (Disseminated) Infection due to *Mycobacterium chelonae*

Richard J. Wallace, MD, David Tanner, MD, Patrick J. Brennan, MD, and ... [See More +](#)

[Author, Article, and Disclosure Information](#)

<https://doi.org/10.7326/0003-4819-119-6-199309150-00006>

- Determine if Clarithromycin 500mg bid x6 months monotherapy safe/effective  
Monitor AFB smears/cultures of skin lesions including clinical response, side effects, development of new lesions
- 14 patients (multicenter) with autoimmune disease or organ transplant (on steroids or cyclophosphamide)
- All patients with excellent response, **new lesions in 6 patients with negative AFB smears/cultures**
- Non-adherent patient stopped at 3.5 months, previous lesion smear/culture positive 1 month later (clarithromycin-resistant)

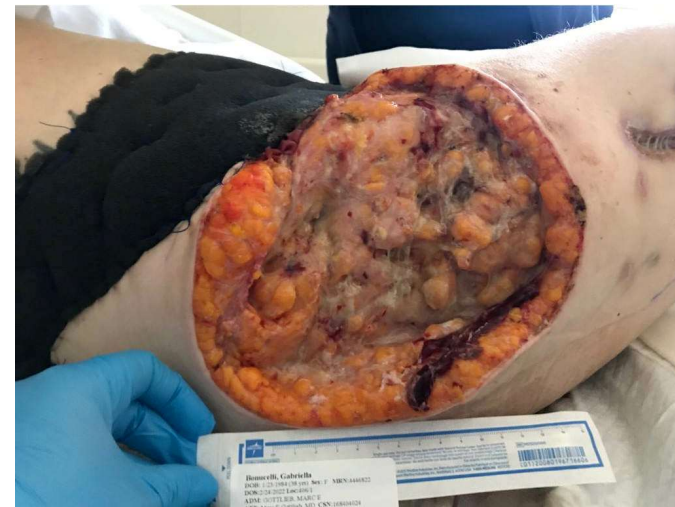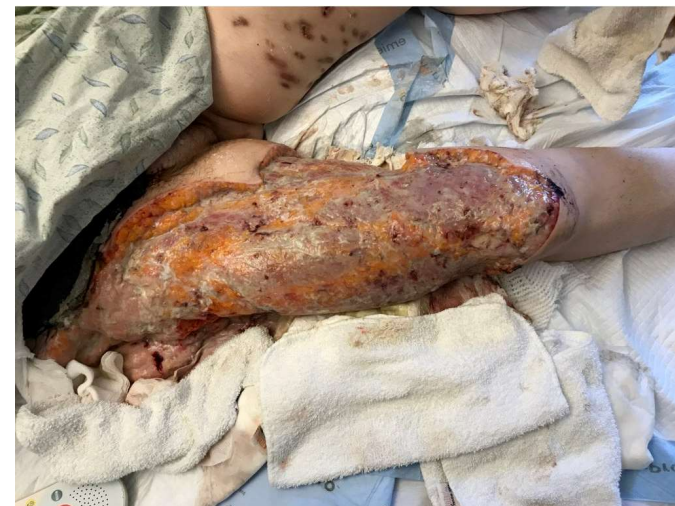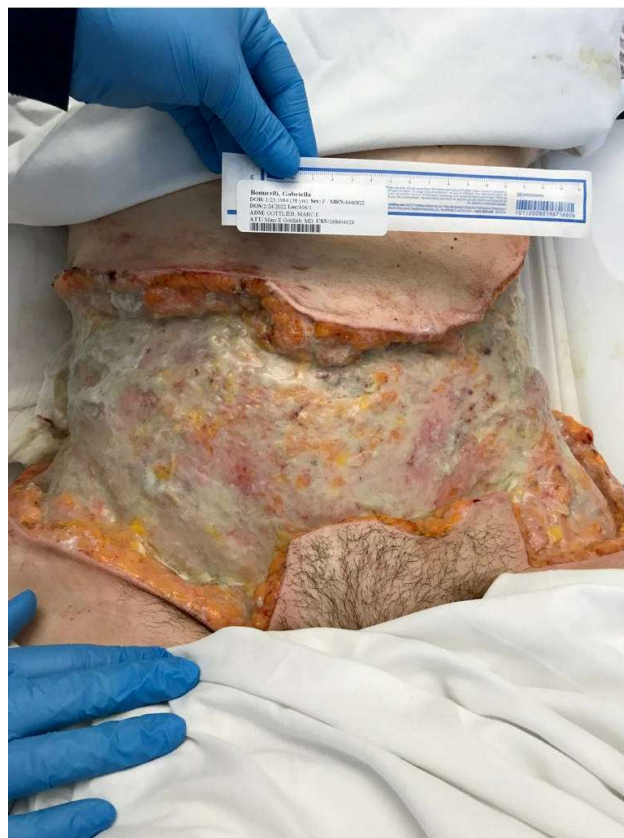
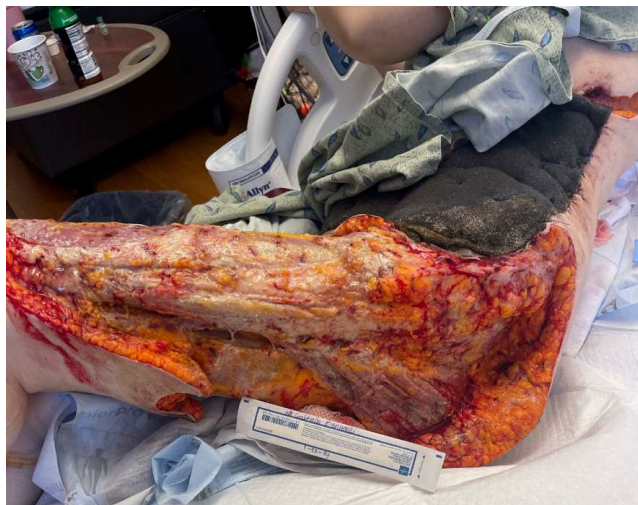# Panniculectomies

Abdomen (2/26/2022)

Right hip (3/3/2022) [NJH  
cultures negative]

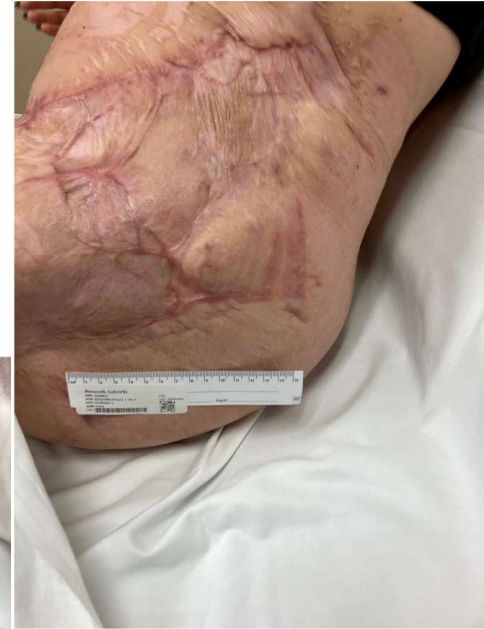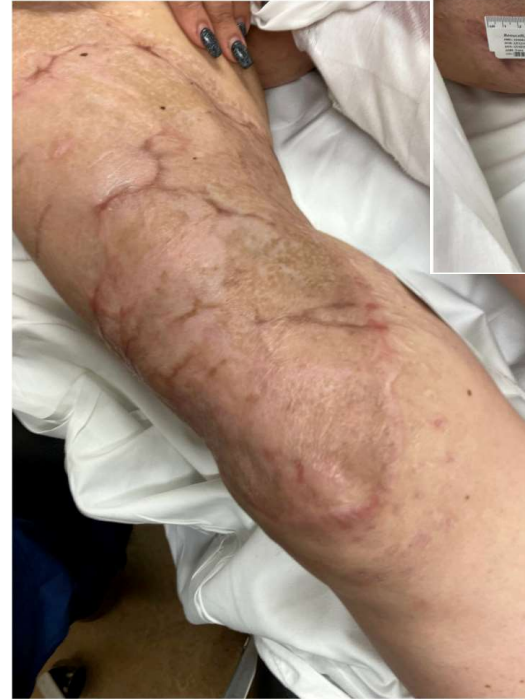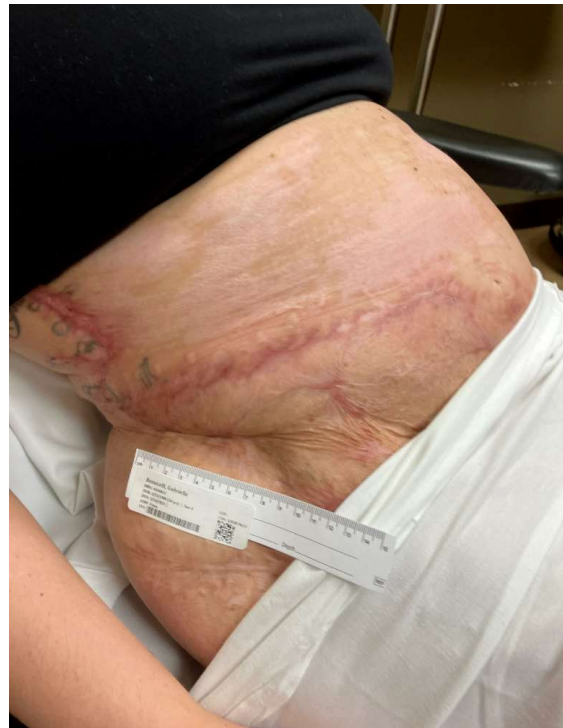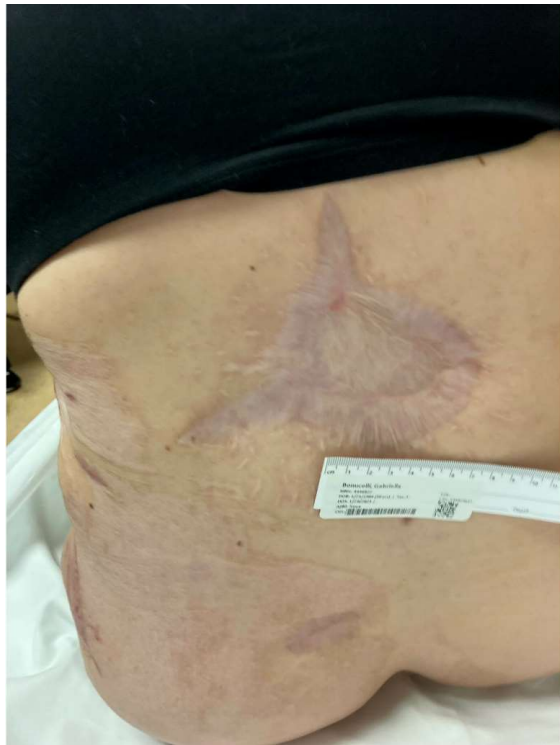Right thigh (3/11/2022)

Left thigh & hip (3/24/2022)





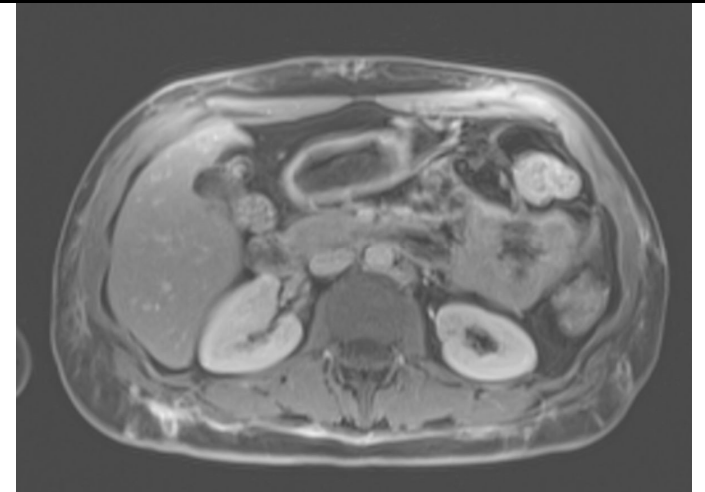
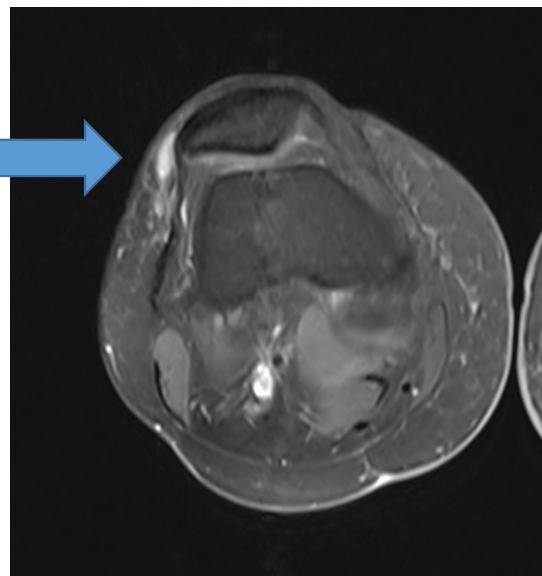
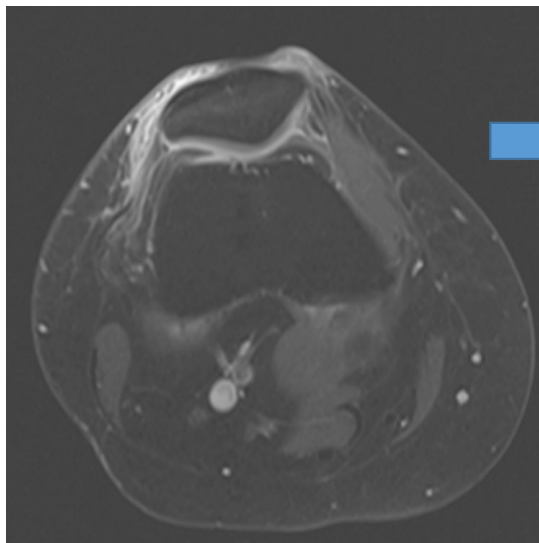
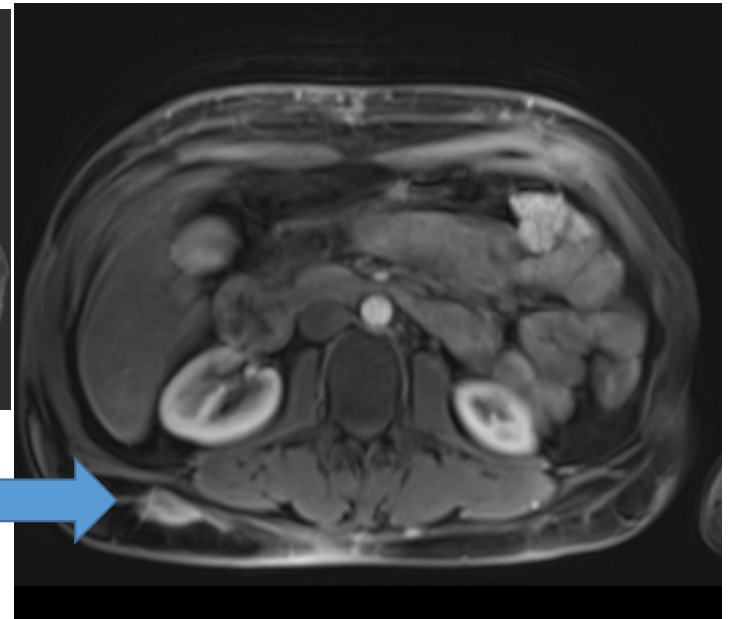
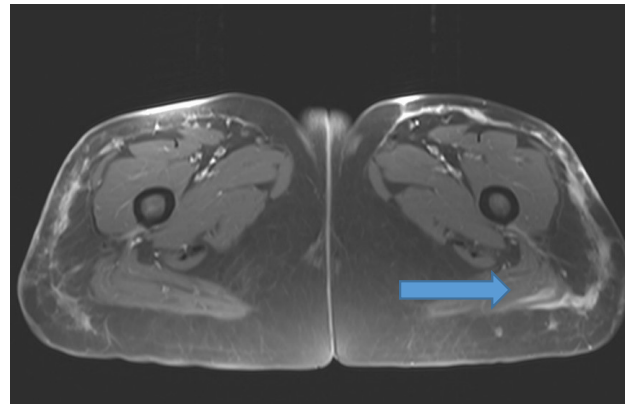
# Pictures from 1/20/2023



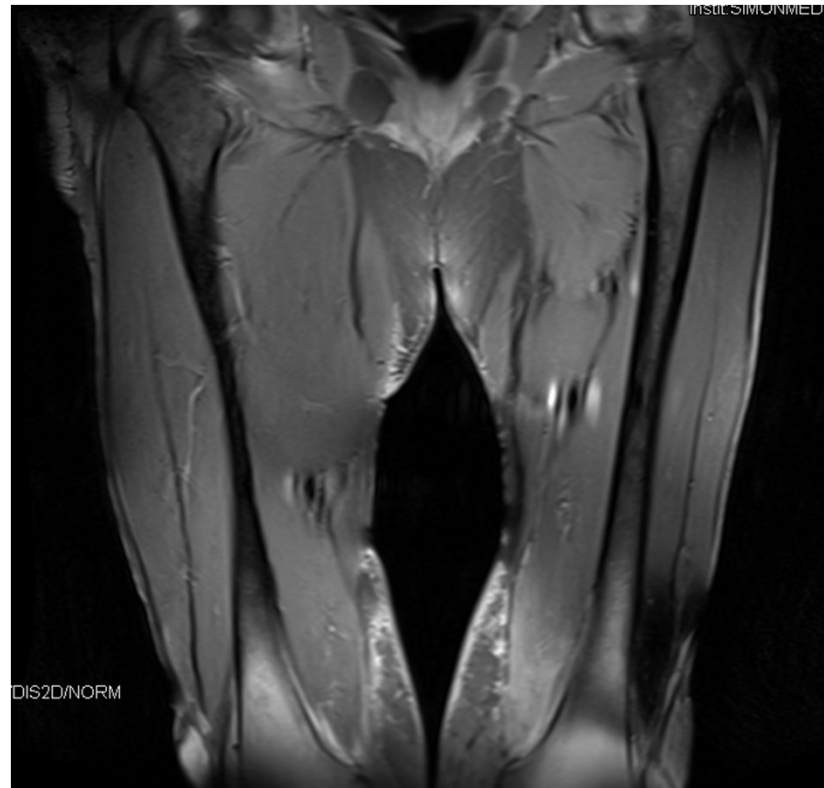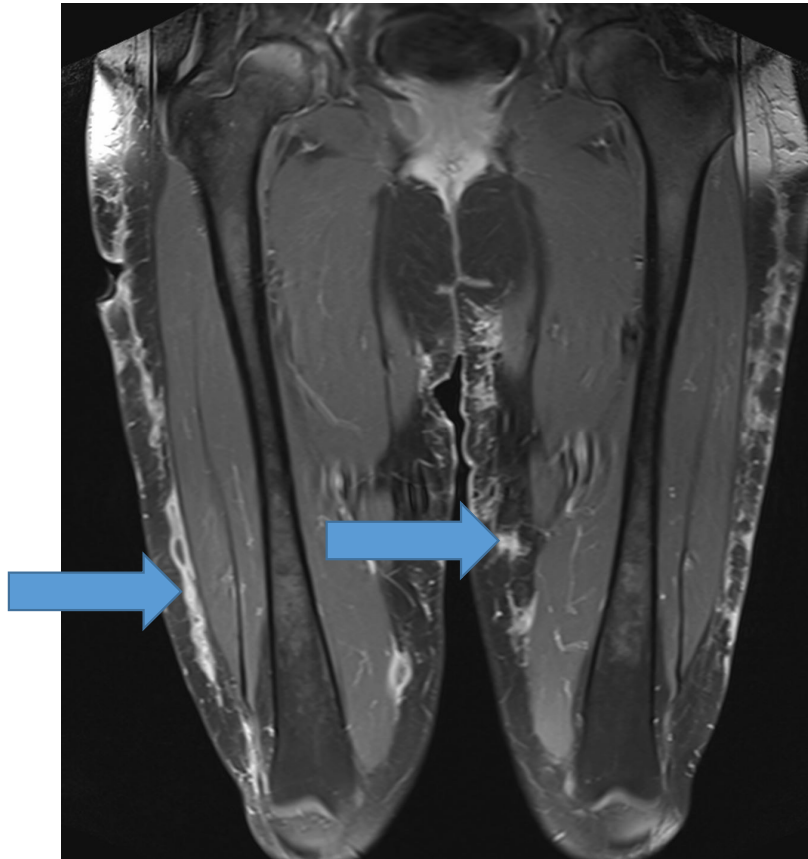
# Persistent Disease?

Right Knee, Right Back  
Left Gluteal?

(Gray: 2/3/2022,  
Black: 9/16/2022,  
except gluteal 2/3/'22)



# Legs before and after surgery



# NTM Prosthetic Joint infection(CO)

Location	Knee (4), Hip (2)
Interval from implantation to symptoms	Median 6 months (0-300 mo)
Interval from symptoms to explantation	Median 8.5 months (3-16 mo)
Cure	All (but 1 required hemipelvectomy)

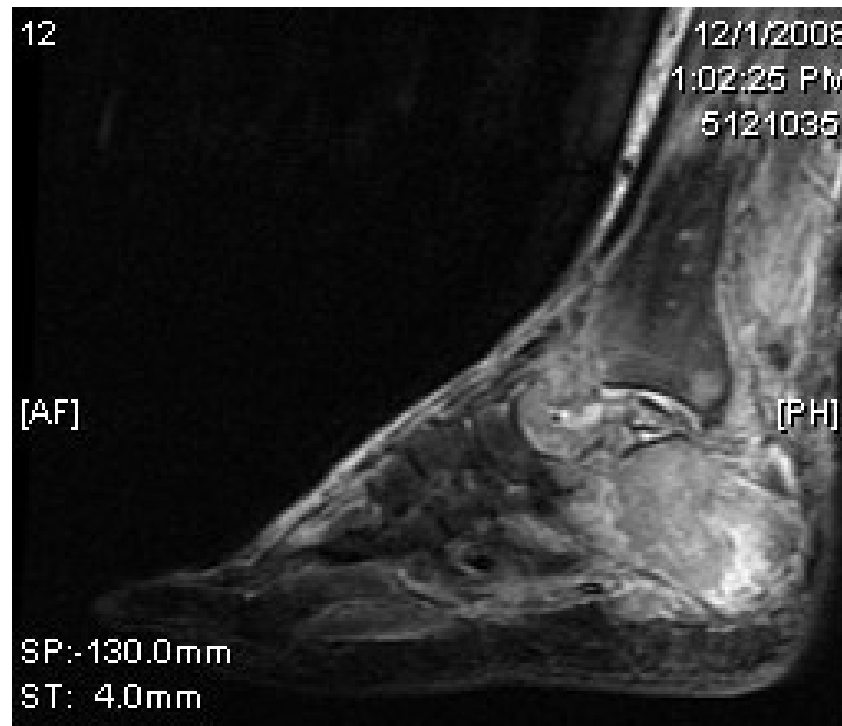
## NTM Prosthetic Joint infection(CO)

Age	Location	Organism	# of abx	Therapy Duration (mo)	Time to re-implantation (mo)	Cure
48 F	Left Hip	<i>M. abscessus</i>	4 (IV)	20	N/A	yes
69F	Right Hip	<i>M. fortuitum</i>	4 (IV)	5	4	yes
79M	Left knee	MAC	4 (IV)	39	12	yes
77F	Right knee	MAC	3	9	7	yes
83M	Left knee	MAC	3	7	5	yes
49F	Right knee	<i>M. gordonae</i>	4 (IV)	16	6	yes

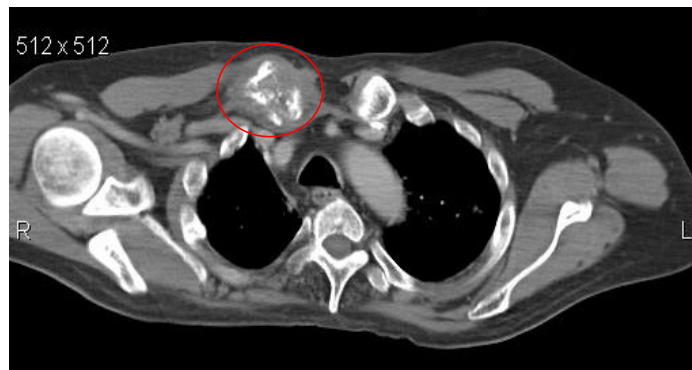
2009-2015

Emerg Infect Dis. 2019 Jun;25(6):1075-1083

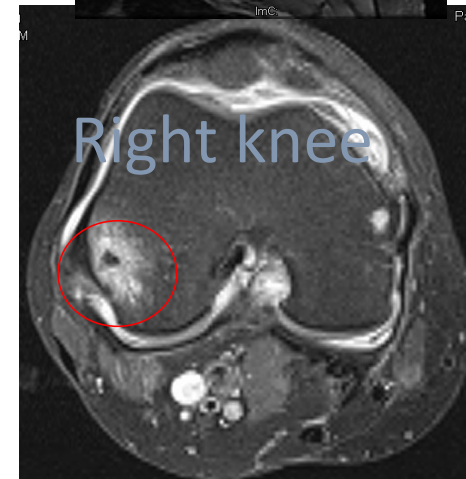
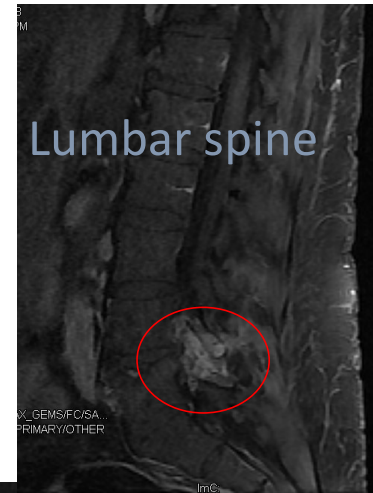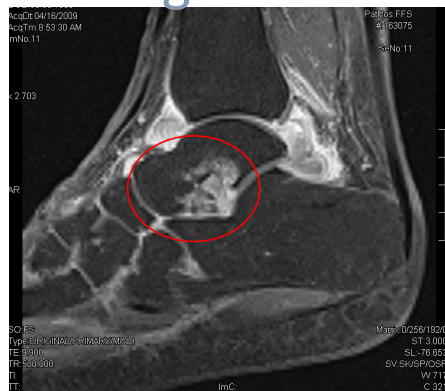55 year-old man steroid injections for left ankle pseudogout?



# Further studies



Right ankle



# Prosthetic Joint infection

- Most patients >60 years old & immunocompetent
- Culture yield
  - Mycobacterial culture (100%)
  - NTM recovered in routine culture low (1/9)
- **Only patients with resection arthroplasty (REA) attained cure**
- Duration of effective antibiotic therapy
  - post REA 16-55 weeks
- Staged re-implantation:
  - successful in 3/6 without lifelong suppressive antibiotics
  - 30+ weeks after REA
- Retention of prosthesis (4), all *M. fortuitum*
  - Successful in 2/4 with suppressive antibiotics



# Vertebral osteomyelitis

- Series 38 cases 1965-2003
  - *M. avium* complex (22), *M. xenopi* (3), *M. fortuitum* (6), *M. abscessus* (3) *M. bovis* (1) *M. simiae* (1), *M. celatum* (1).
  - Mean age 56
  - ~30% immunosuppressed
  - Most frequent sites: lower thoracic, upper lumbar
  - Trauma (4)
  - Post-laminectomy (1)

# Vertebral osteomyelitis

- Treatment: no consensus
  - surgical and antimicrobial therapy is often required to completely eradicate the infection.
- Indications for early surgery: progressive destruction of vertebral bodies, neurological compression, and abscess formation, drug resistant organism

# Catheter related blood stream infections

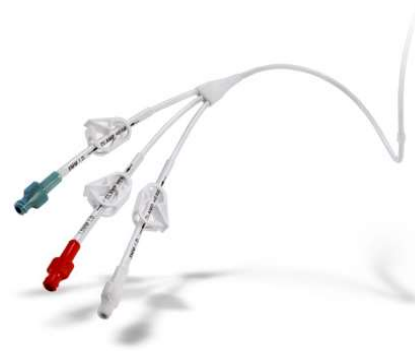\*N=11 CRBSI w/ RGM

- Oncology patients
- 6/11 neutropenic
- 4/4 cured w removal + antibiotics
- 7/7 failure with antibiotics alone

No official recommendations exist for the choice of antibiotics or duration

Suggest: 2 active antibiotics for a minimum of 2 months with resolution of symptoms and removal of the line

**MUST REMOVE**

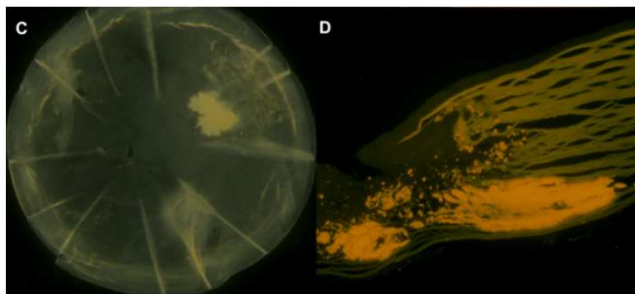
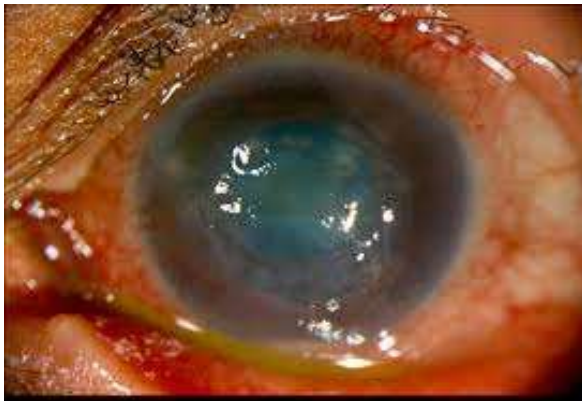

Diagn Microbiol Infect Dis. 2008 Jun;61(2):187-91.

Pediatr Infect Dis J. 2003 Dec;22(12):1108-9.

\*Rev Infect Dis. 1991 Nov-Dec;13(6):1120-5.

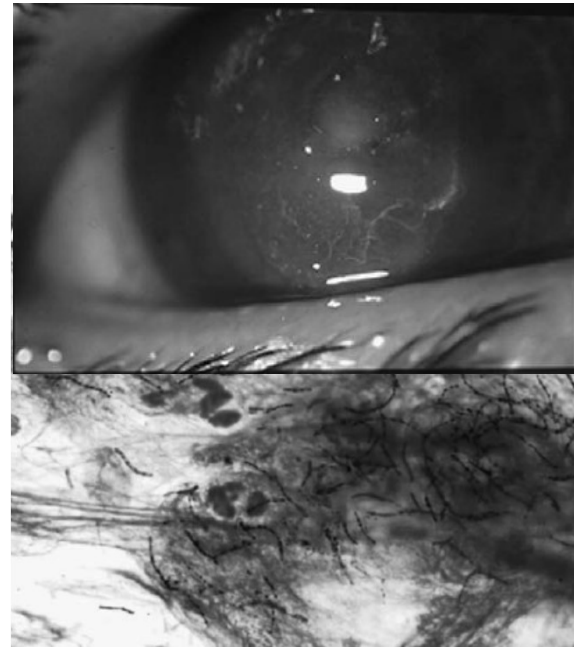
# NTM Keratitis



- Inflammation of the cornea
- Indolent (>3.5 wk) pain redness, photophobia, decreased vision
- Most common NTM: RGM (*M. chelonae*)
- Risk Factors:
  - LASIK,
  - eye surgery
  - contact lens use
- Dx: early irrigation/culture

# NTM Keratitis

- Triple Topical Treatment: amikacin, clarithromycin + moxifloxacin gtts +/- PO macrolide
- Rx: No consensus on duration
- Surgery: indications for flap removal
  - Nonadherence of the flap
  - Lack of clinical improvement on medical therapy
- Avoid topical corticosteroids



Int Ophthalmol Clin. 2007;47(2):73-84.  
J Cataract Refract Surg 2010; 36:843–846

# Disseminated Disease

- Typical presentation : HIV/AIDS
  - (CD4 <50)
- Any of the NTM can cause dissemination
  - >90% secondary to *M. avium* complex
- Introduced: lungs or intestinal tract
- Clinical presentation
  - Fever, night sweats, **weight loss**, diarrhea
  - Bacteremia (intermittent), elevated alkaline phosphatase, LDH, **anemia**

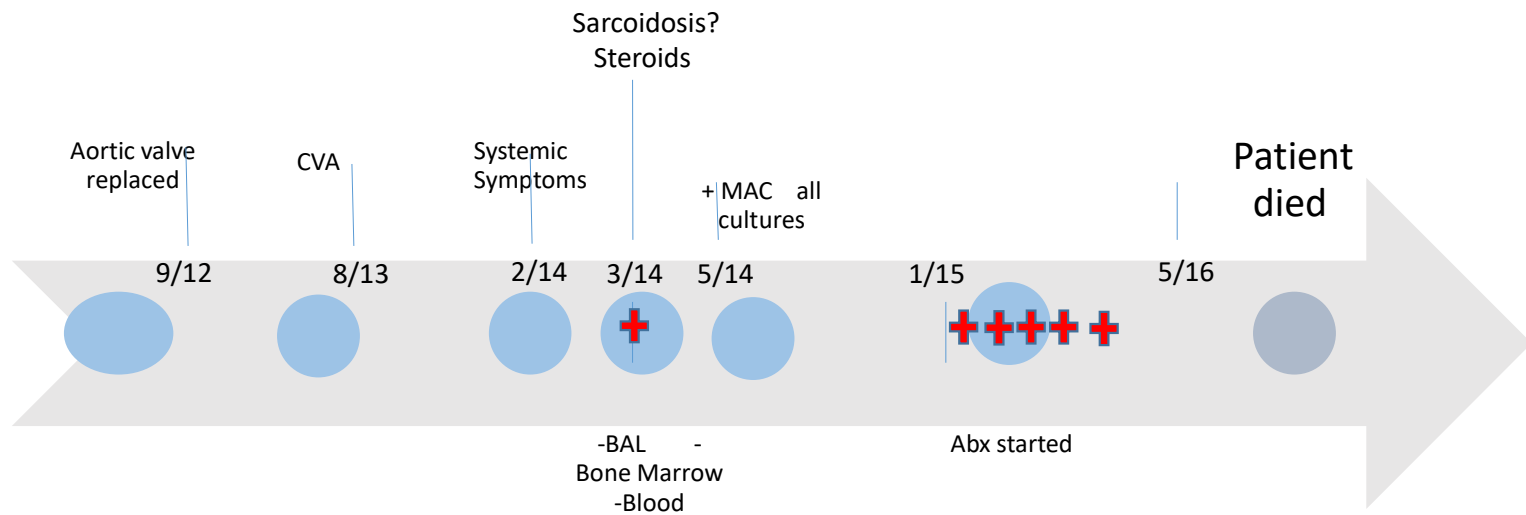
# Disseminated Disease

- Incidence
  - DMAC ~40% of AIDS patients with CD4 of <10
  - 3.7/100 person years → 0.9/ 100 person years in the HAART era
- Risk factors: Immunocompromised, central line infection
- Diagnosis: + blood cultures
  - Recommend liquid and solid medium
  - 96% + in liquid culture by 14 days
- Treatment:
  - Clarithromycin/azithromycin + ethambutol +/- rifabutin
  - Key to success in HIV/AIDS is antiretroviral therapy

- A 53 year old male describes cryptic fevers for 3 months and fatigue. He has a normal exam apart from an well healed sternotomy incision related to aortic valve replacement (AVR) 6 years ago. His labs note anemia, hepatitis and an elevated creatinine.
- Blood cultures are + for MAC.
- What is this related to?
  1. HIV infection
  2. Idiopathic CD4 lymphopenia
  3. Contamination of a device from the OR 6 years ago



# Clinical Case



# The Outbreak: Heater-Cooler Units

-Warm or cool a patient to an optimal temperature

-250,000 procedures in the US/year

-3T: 60% US market share

## 3T - USA

[Home](#) > [Products](#) > [Cardiac Surgery Solutions](#) > [Perfusion](#) > [Heart Lung Machine](#) > 3T - USA

[Catalogue: USA](#)

### FAST AND EFFICIENT PATIENT TEMPERATURE CONTROL

The Sorin 3T Heater-Cooler System provides 3 circuits for fast and efficient heating and cooling to meet your patient and cardioplegia temperature needs.

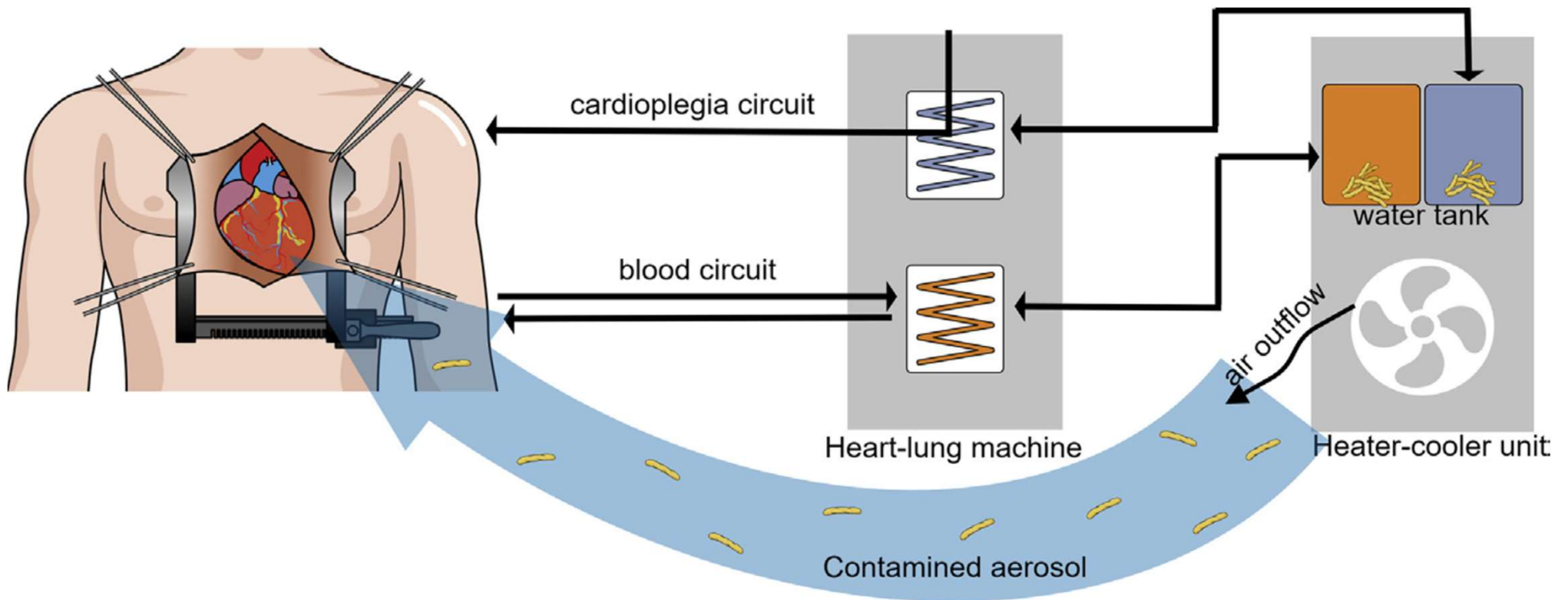
Compressor-based cooling and 3 independent water tanks eliminate the need for ice and water supply in the operating room, providing separate settings for warm cardioplegia, cold cardioplegia and patient temperature.

### EASE OF USE

Patient temperature settings can be adjusted to the tenth decimal point for accurate temperature control.

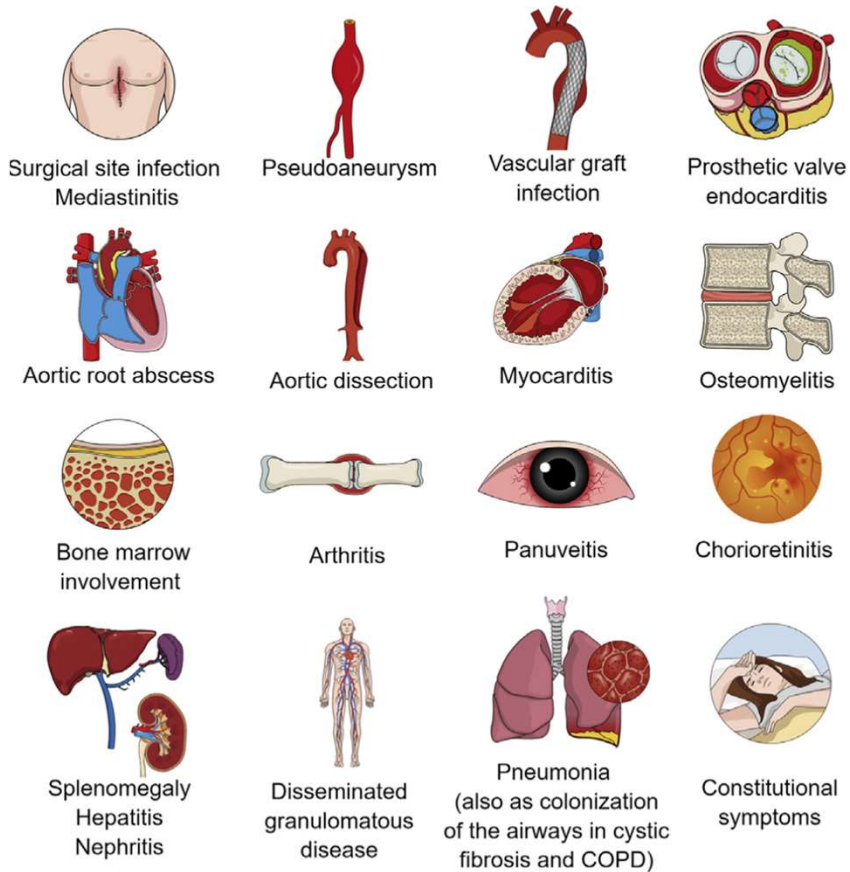
To facilitate cleanup, a water evacuation feature allows pulling back water from the lines into the tanks at the end of a procedure.





# *Mycobacterium chimaera*

## Possible clinical pictures (3-72 weeks after cardiothoracic surgery)



## Microbiology

- Coccobacillus
- Slowly growing (up to 6-8 weeks to culture)
- Non pigmented
- Acid-fast positive
- Non motile
- Non-spore forming
- Natural drug resistance

## Diagnosis

- Clinical suspicion
- Not otherwise explained clinical manifestation lasting >3 weeks
- Evaluation of medical history, exposure and risk factors

Lab abnormalities: pancytopenia, hypoalbuminemia, alkaline phosphatase >150IU/L, C-reactive protein <50mg/L

M. chimaera identified by DNA sequencing in an invasive sample (blood, pus, biopsy, prosthetic material)

## Treatment

The therapeutic management of *M. chimaera* infections, in the absence of guidelines, is inferred from the management of NTM infections and is not always sufficient to achieve the therapeutic target.

- Macrolides
- Ethambutol
- Rifamycins
- Aminoglycosides

# Clinical Presentation

Time to Presentation – median 21 months (5-40)

<b>Symptoms</b>	Fever, Fatigue, Weight loss, Shortness of breath
<b>Signs</b>	Splenomegaly Chorioretinitis
<b>Laboratory Values</b>	Anemia, Lymphocytopenia, Thrombocytopenia, Elevated CRP Elevated transaminases Elevated creatinine

Achermann Y, et al. J Clin Microbiol 2013;51:1769  
Sax H, et al. Clin Infect Dis 2015;61:67  
Kohler P, et al. Eur Heart J 2015;36:2745

**Table 1**  
Case definition of *M. chimaera* infections potentially associated with heater-cooler units.

---

<b>CLINICAL CRITERIA</b>	<b>EXPOSURE CRITERIA</b>
Any of the following: <ul style="list-style-type: none"><li>• Prosthetic valve endocarditis</li><li>• Prosthetic vascular graft infection</li><li>• Sterotomy wound infection</li><li>• Mediastinitis</li><li>• Manifestation of disseminated infection including embolic and immunologic manifestations, e.g. splenomegaly, arthritis, osteomyelitis, bone marrow involvement with cytopenia, chorioretinitis, lung involvement, hepatitis, nephritis, myocarditis.</li></ul>	Surgery requiring cardiopulmonary bypass in the five years prior to the onset of symptoms of infection.
<b>CONFIRMED CASE</b> Clinical + exposure criteria + <i>M. chimaera</i> detected and identified by DNA sequencing in an invasive sample (blood, pus, tissue biopsy or implanted prosthetic material)	
<b>PROBABLE CASE</b> <ul style="list-style-type: none"><li>• Clinical + exposure criteria + <i>M. chimaera</i> detected by direct PCR and amplified DNA sequencing in an invasive sample (blood, pus, tissue biopsy or implanted prosthetic material)</li><li>• Clinical + exposure criteria + MAC detected by culture or direct PCR from an invasive sample (blood, pus, tissue biopsy or implanted prosthetic material)</li><li>• Clinical + exposure criteria + histopathological detection of non-caseating granuloma and foamy/swollen macrophages with acid-fast bacilli in cardiac or vascular tissue in the proximity of the prosthetic material or in specimen from the sternotomy wound.</li></ul>	


---

MAC = *Mycobacterium avium* complex.

PCR = Polymerase chain reaction.

Adapted from 2015 ECDC case definition [22].

# Prolonged outbreak of *M. chimaera* infection after open-chest heart surgery



N= 6 males affected between 2006-2012

Ages 49-64

Sx: fatigue, fever, hepatitis, splenomegaly, renal insufficiency, pancytopenia

Latency of symptoms : 1.5-3.6 years

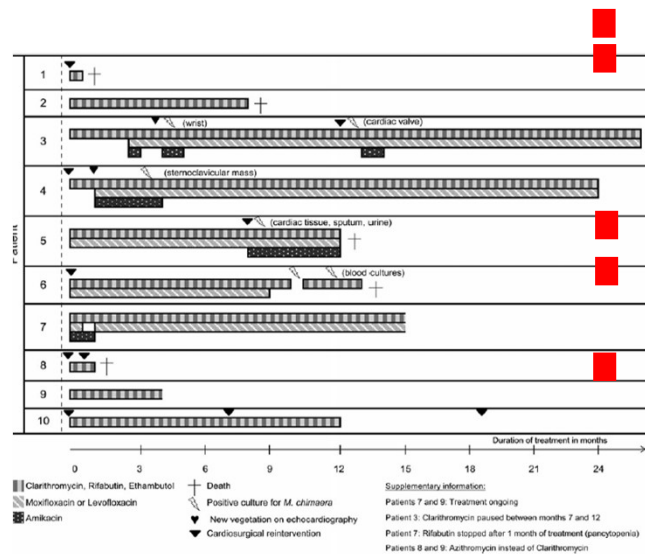
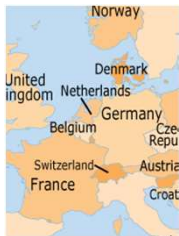5/6 abnormal echocardiogram

3/6 underwent PV replacement

1 repeated surgical debridement

2/6 died despite antibiotic therapy

# Healthcare associated *M. chimaera* infections subsequent to open heart surgery



- 10 patients with disseminated *M. chimaera*
- 3 European hospitals
- Latency 18 months (median)
- Diagnosis 21 months (median)
- Fever, SOB, fatigue, wt loss
- Splenomegaly
- Anemia, lymphocytopenia, thrombocytopenia
- Rx: macrolide/rifamycin/ethambutol
- +/- amikacin, quinolone
- 8/10 treatment failure, 5 deaths

Kohler P, et al. Eur Heart J 2015;36:2745-53.



> [J Infect.](#) 2020 Feb;80(2):197-203. doi: 10.1016/j.jinf.2019.12.007. Epub 2019 Dec 19.

## Long-term follow-up of post-cardiac surgery *Mycobacterium chimaera* infections: A 5-center case series

Kathleen G Julian<sup>1</sup>, Tonya Crook<sup>2</sup>, Eugene Curley<sup>3</sup>, A Ben Appenheimer<sup>4</sup>, Catharine I Paules<sup>2</sup>, Barbara Hasse<sup>5</sup>, Daniel J Diekema<sup>4</sup>, Charles L Daley<sup>6</sup>, Jorgelina de Sanctis<sup>7</sup>, Walter C Hellinger<sup>8</sup>, Adrah Levin<sup>6</sup>, George McSherry<sup>2</sup>, Carol Freer<sup>2</sup>, Cynthia J Whitener<sup>2</sup>

Affiliations + expand

PMID: 31863789 DOI: 10.1016/j.jinf.2019.12.007

## Disseminated *Mycobacterium chimaera* Infection After Cardiothoracic Surgery

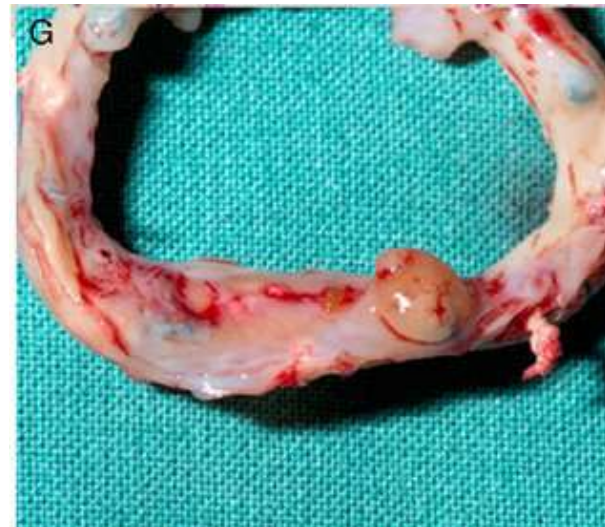**Nicholas Tan,<sup>1</sup> Rahul Sampath,<sup>2</sup> Omar M. Abu Saleh,<sup>2</sup> Marysia S. Tweet,<sup>3</sup> Dragan Jevremovic,<sup>4</sup> Saba Alniemi,<sup>5</sup> Nancy L. Wengenack,<sup>1,6</sup> Priya Sampathkumar,<sup>2</sup> and Andrew D. Badley<sup>2</sup>**

<sup>1</sup>Department of Internal Medicine, <sup>2</sup>Division of Infectious Disease, <sup>3</sup>Division of Cardiovascular Diseases, <sup>4</sup>Department of Hematopathology, <sup>5</sup>Department of Ophthalmology, and <sup>6</sup>Division of Clinical Microbiology, Mayo Clinic College of Medicine, Rochester, Minnesota

Tan N et al. *Open forum Infect Dis* 2016;3:ofw131.

# Manifestation of Infections

- Prosthetic valve endocarditis
- Vascular graft infection
- Manifestations of disseminated disease:
  - Emboli
  - Bone marrow involvement
  - Splenomegaly
  - Nephritis
  - Myocarditis
  - Osteomyelitis



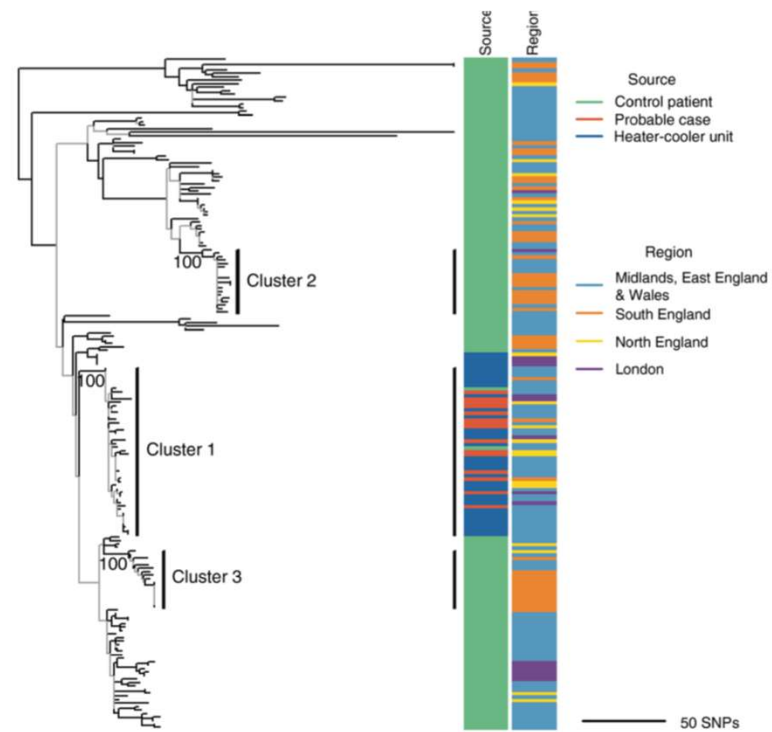
Achermann Y, et al. J Clin Microbiol 2013;51:1769

Sax H, et al. Clin Infect Dis 2015;61:67

Kohler P, et al. Eur Heart J 2015;36:2745

# *M. chimaera* typing

Phylogenetic analysis found close clustering of strains from probable cases

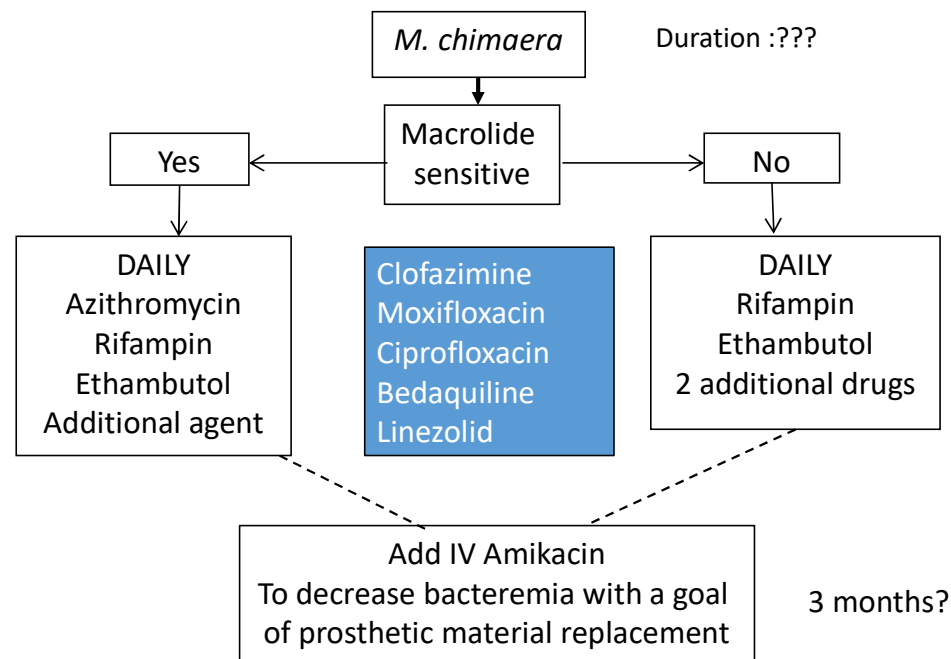


Chand et al. Clinical Infectious Diseases 2017;64 (3)335-42.

# The Outbreak Summary

- An outbreak with global distribution
- Worldwide case count  $\geq 150$  in 2019
- The isolates from Europe, US and Australia are genetically identical
- The source of contamination originated at the manufacturing site

# Treatment Disseminated *M. chimaera*



# Move the unit



Courtesy of Jakko van Ingen

# Extrapulmonary NTM: Summary

- Sub-acute, chronic
- Consider:
  - immunocompromised patient or post-operative patient with a sub-acute presentation
- Must be have a high index of suspicion
- Avoid monotherapy
- Treatment is measured in months
- Remove all foreign material
- *M. abscessus*
  - Pathogenicity + drug resistance
  - surgical debridement is often necessary for cure

# Questions ?

